

## Is MRA more accurate in diagnosing cervical vascular injury in trauma patients than CTA?

By

**Hamad Abayan S Almansour**  
**MOHAMMED HUSSAIN ALI ALMANSOUR**  
**Mohammed Hamad Hadi Almansour**  
**yousef Ali Hadi Almansour**  
**Ali Hussain Hamad Al-Mehthel**  
**Abdullah Hadi Abdullah Alyami**  
**Ahmed Abdullah Hussain Al salem**  
**Reem Saeed Alamri**

### Abstract

#### Aim

The aim of this systematic review was to evaluate the diagnostic accuracy of magnetic resonance angiography (MRA) versus computed tomography angiography (CTA) for cervical vascular injury secondary to trauma.

#### Background

CTA is widely used in practice to diagnose cervical vascular injuries, largely supplanting the gold standard of digital subtraction angiography (DSA). However, the use of CTA is limited by the exposure to ionising radiation and lack of sensitivity in some contexts. Hence, evaluation of the potential diagnostic accuracy of MRA in this context is justified.

#### Methods

A systematic literature review was completed using online databases and a clear search strategy. Diagnostic accuracy studies involving the use of CTA and/or MRA in the diagnosis of cervical vascular injuries were sought, with a focus on human studies, primary studies and literature published between 2011 and 2021. Studies were subjected to formal critical appraisal using the Critical Appraisal Skills Programme toolkit and were synthesised using a narrative framework.

#### Results

The results of the literature search identified seven studies that met the review inclusion criteria. Five studies evaluated the diagnostic accuracy of CTA, noting sensitivity ranging from 51% to 72% for cervical vascular injury, high specificity (63–97%) and a high overall diagnostic accuracy (95%) compared with DSA. MRA diagnostic accuracy was not as robustly assessed in the two included studies, although evidence suggests consistency with expert consensus imaging and CTA/DSA imaging standards in specific contexts. No study directly compared CTA and MRA in the diagnosis of cervical vascular injury secondary to trauma.

#### Conclusion

These findings suggest that CTA remains the imaging strategy of choice for suspected cervical vascular injury, as MRA does not have evidence supporting use in this context. The practical use of CTA and availability of this imaging approach further supports its use in trauma contexts.

## Background

It is estimated that 5–10% of presentations to emergency departments involve significant trauma to the head and/or neck (Hussain and Javed, 2011). Of these injuries approximately 80% are thought to result from blunt injury, versus 20% due to penetrating injuries (Saito et al., 2014). However, data from international studies may be skewed by the relatively high level of injury attributed to gunshot wounds in the United States and other nations where firearm use is common relative to the United Kingdom (UK) (Kasbekar et al., 2017). However, data on these injuries from the UK are less robust and it is considered that penetrating neck injuries are relatively uncommon in the UK emergency setting, although increasing levels of urban violence has led to a steady increase in case presentations (Siau et al., 2013). Indeed, over 30,000 offences occur annually involving a knife or sharp weapon and 10% of trauma patients have a penetrating neck injury (Kasbekar et al., 2017). Furthermore, the mortality rate of these injuries remains relatively high, ranging from 3–10% (Jenkins and Rezende-Neto, 2020). Mortality typically results from the resulting injury to vascular structures and the risk of exsanguination, highlighting the clinical importance of these injuries (Kasbekar et al., 2017).

The definition of cervical vascular injury is broad and includes any form of vascular injury or trauma-related pathology that has the potential to compromise morbidity or mortality. This includes carotid artery dissection or occlusion, intimal flaps, arteriovenous fistula, transection, pseudoaneurysms, and vertebral artery pathology (LeBlang and Nunez Jr, 2000; Payabvash et al., 2014; Evans et al., 2018). The injuries with the greatest risk of immediate mortality, due to massive blood loss, include carotid artery injuries, particularly dissections and transections, and these are also the most common forms of injury, accounting for 80% of cases of neck trauma (LeBlang and Nunez Jr, 2000; Siau et al., 2013). Vertebral artery injury is also a common finding in patients with cervical spine trauma and indiscriminate screening is considered in guidance when cervical injury has occurred (Tobert et al., 2018). Within the context of trauma patient management, multiple injuries may be sustained across various sites of the body, contributing to the complexity of patient assessment and management (Jenkins and Rezende-Neto, 2020). The mechanism of traumatic injury may have important implications for the types of injuries sustained, including within the cervical region, as blunt traumatic injuries may be less overt than penetrating injuries (Payabvash et al., 2014). It is vital that neck vasculature is assessed within the context of any traumatic injury, even if other regions are affected, due to the high level of risk of exsanguination and the frequency of injury to vessels in this region linked to both blunt and penetrating trauma (Kasbekar et al., 2017). Grading of cervical vascular injuries is

also commonly performed, with the grading system of Biffi et al. (1999) utilised, which is specific to blunt carotid artery injuries. The grades of injury are shown in Table 1, which correlate with the risk of stroke and the mortality rate of the injury, highlighting the clinical value of the grading process.

Table 1. Cerebrovascular injury grading scale (Biffi et al., 1999: 847)

Injury grade	Description	Stroke rate (%)	Mortality rate (%)
I	Luminal irregularity; <25% narrowing of the lumen	3	11
II	Dissection or intramural haematoma; 25% of greater narrowing, intraluminal thrombus or raised intimal flap	11	11
III	Pseudoaneurysm	33	11
IV	Occlusion	44	22
V	Transection with extravasation	100	100

Diagnosis of vascular injury following trauma is crucial to effectively managing the patient in an emergent context (Jenkins and Rezende-Neto, 2020). While diagnosis may be facilitated by clinical evaluation, including any obvious exterior penetrating injuries to the cervical region, internal injuries due to trauma require imaging strategies. Indeed, cervical vessel damage may occur secondary to both penetrating and blunt trauma and these injuries may be difficult to detect in a clinical examination (Schroeder et al., 2010) and it is reported that clinical examination alone has only a 61% sensitivity for detecting significant vascular injury in the neck and head (Sclafani et al., 1991), consistent with more recent estimates of sensitivity (57%) for vascular injury detection following penetrating trauma to the cervical region (Mohammed et al., 2004). The level of trauma and the consequences to the patient can vary significantly, depending on the nature of trauma and the clinical characteristics of the patient (such as the presence of comorbidities, including bleeding disorders), although any cervical vessel injury is linked to the risk of complications and poor outcomes (Patterson et al., 2012). Trauma to major arteries in the neck can present a serious risk of morbidity and mortality unless identified urgently (O'Brien and Cox, 2011).

Over the last half a century, the approach to diagnosing and managing cervical vessel trauma has modified in response to the increasing role of diagnostic imaging strategies (Rutman et al., 2018). While traditional approaches to diagnosis and management were often combined within surgical exploration and intervention in the affected region, increasing selective non-operative treatment is viewed as the optimal strategy (Van Waes et al., 2012). Indeed, endovascular repair of vascular trauma is a common procedure indicated for serious cervical vessel injury and has been shown to be highly effective and life-saving treatment when such trauma is identified (Simon and Brown, 2020). This strategy relies on accurate non-invasive

imaging assessment of the patient (Patterson et al., 2012). Consequently, there is an increasing recognition of the need for rapid and sensitive imaging strategies that may be used prior to or during operative procedures in trauma patients, in order to guide diagnosis (Meghoo et al., 2012).

### **Imaging strategies in diagnosing cervical vascular injury**

The need for accurate imaging studies developed over the course of the Twentieth Century and into the Twenty-First Century, as result of changes to management of blunt and penetrating neck injury during World Wars and the Vietnam War, among others (Feliciano, 2017; Kasbekar et al., 2017). The role of imaging was recognised as increasingly important in avoiding exploratory surgical interventions that had a risk of complications and adverse outcomes (Feliciano, 2017). The use of conventional angiography (digital subtraction angiography; DSA) emerged as an important imaging strategy in this context, utilising X-ray imaging in a two-dimensional plane and the use of contrast agents within the affected vessels (Feliciano, 2017). This imaging strategy was proposed as a gold standard in haemodynamically stable patients with clinical signs suggestive of cervical vessel trauma (Strickland et al., 2019). Indeed, studies showed that the use of angiography facilitated an opportunity to diagnose pathology in a significant proportion of patients, while potentially guiding the nature of surgical interventions and impacting on mortality (Thomas et al., 1978; Fakhry et al., 1988; Strickland et al., 2019). However, limitations to this strategy were evident in practice and challenged the routine use of angiography in this context. Firstly, the technique was time-consuming in nature and delayed the initiation of surgical interventions in patients, which may contribute to a risk of mortality (Strickland et al., 2019). The time-consuming nature of the technique was particularly hard to justify given the low sensitivity for detection of vascular injury, with more than 80% of cases showing a negative result following screening, despite the presence of a treatable lesion (Ofer et al., 2001). Finally, the risks associated with the invasive nature of the procedure, particularly in patients with penetrating injuries and complex management issues (Strickland et al., 2019).

The consequences of the notable limitations of angiography (DSA) was that alternative imaging strategies were sought that met specific criteria in this clinical context. Firstly, imaging strategies had to be sensitive (i.e. accurate) in detecting vascular injury in the cervical region, with a diagnostic accuracy far greater than conventional angiography (Ofer et al., 2001). Secondly, the technique should limit the delay between initial patient assessment and subsequent management as much as possible. Thirdly, the imaging strategy should be non-

invasive in nature to facilitate rapid use and to avoid complications linked to invasive imaging (Saito et al., 2014).

Non-invasive imaging studies emerged as important alternatives in practice and included ultrasonography. Indeed, the role of Doppler ultrasonography has been described in the context of vascular imaging in the cervical region but is generally not performed in contemporary practice in the context of traumatic injury (Feliciano, 2015). Other imaging strategies are often preferred due to the limitations of the technique, including relatively low sensitivity for detection of traumatic injury, operator and injury location variability in diagnostic accuracy and a limited field of imaging evaluation (precluding assessment of wider injuries linked to trauma) as noted in the wider literature (Feliciano, 2015). Consequently, the use of common, non-invasive imaging strategies, including computed tomography (CT), have become more widespread in this context (Eastman et al., 2006; O'Brien and Cox, 2011).

### **CT angiography**

CT angiography (CTA) has been used in the context of evaluating neck vasculature, both in traumatic and non-traumatic contexts for decades (Munera et al., 2000). The initial interest in this imaging approach for traumatic injuries stemmed from the recognition that CTA can be used to detect atherosclerotic disease in the carotid arteries with a high degree of accuracy, suggesting suitability for vascular imaging in the neck (Munera et al., 2000). The technique has advantages over the use of conventional angiography in that it is non-invasive and provided three-dimensional imaging planes, allowing for more detailed analytical assessment of vasculature in the cervical region (Wakao et al., 2014).

Studies evaluating the use of CTA in traumatic vascular imaging emerged in the literature and provided a basis for justifying the use of the imaging technique in emergency contexts (Ofer et al., 2011; Wakao et al., 2014). Munera et al. (2000) found in an early prospective study comparing CT angiography to conventional angiography, that sensitivity of CTA was 90% and specificity 100%. Subsequent studies found comparable results, with sensitivity and specificity of CTA ranging from 90–100% for a range of pathological lesions linked to cervical vascular injury, including occlusions, pseudoaneurysms, fistulae, thromboses and dissections (Gracias et al., 2001; Munera et al., 2002; Hollingworth et al., 2003). However, a significant proportion of studies are now over a decade in age and may reflect older CT technologies and protocols. The evolution of CT imaging over time, including the use of multi-slice imaging increase the detail captured in imaging studies and reduce the time needed for image capture (Hanning et al., 2017). Therefore, as technology evolves with CT imaging, there is a need to ensure

that evaluation of CTA in the context of trauma remains up-to-date and reflects the advantages of newer technologies in practice (Hanning et al., 2017). Furthermore, the adoption of CTA within trauma management protocols has led to refinement of the use of this imaging approach, maximising the clinical relevance of the findings and improving the potential to modify treatment options and surgical intervention approaches (Hagedorn et al., 2014). Despite these protocols and technological advances, the use of CTA remains a point of discussion in the literature regarding the diagnostic value and accuracy of the approach, as imaging may not routinely influence or alter surgical treatment of cervical spine injuries (Hagedorn et al., 2014). While imaging can influence detection of lesions that increase the risk of stroke, and may indicate the need for antithrombotic therapy, questions over their diagnostic accuracy may limit the degree to which these findings influence care, particularly where other traumatic injuries may influence clinical interventions and priorities (Hagedorn et al., 2014).

### **Magnetic resonance angiography**

While CTA has been identified as an emerging gold standard imaging strategy for diagnosing vascular trauma in the cervical region (Sporns et al., 2019), there is an increasing interest in the value of magnetic resonance angiography (MRA) in this context (Four). MRA is a technique based on magnetic resonance imaging, a non-invasive technique that does not require exposure of the patient to ionising radiation (Saito et al., 2014). The key advantages of MR imaging versus CT imaging rest with the potential to discriminate soft tissue margins with a greater degree of accuracy, which allows for more detailed characterisation of tissues and anatomical injury in many contexts (Fourman et al., 2019).

Both CTA and MRA have been associated with clinical value and diagnostic accuracy in a range of vascular imaging contexts, including peripheral artery disease (Varga-Szemes et al., 2017), stroke (Mair et al., 2017), and in the assessment of the cerebrovascular system (Figueiredo et al., 2012). However, in the context of traumatic injury and the assessment of cervical vascular injury, the comparative diagnostic accuracy and value of these imaging modalities, particularly MRA, is not as clear. While the evidence base supporting CTA is based on a range of studies that support the use of the approach in practice, the evidence for the use of MRA, particularly when contrasted with gold standard assessment, remains uncertain (Fourman et al., 2019).

udies evaluating the use of MRA in trauma contexts do provide some support for the theoretical advantages of the modality. For instance, Vaccaro et al. (1998) provided an early estimation that MRA could be used in trauma contexts, although this reflected long-term outcome evaluation rather than initial diagnosis of

lesions/injury. However, Weller et al. (1999) established that MRA with flow-sensitivity could provide an accurate assessment of cervical vascular injury following trauma, although the diagnostic accuracy of the method was not evaluated in detail. Other studies have suggested that MRA may be used to effectively isolate traumatic injury to cervical vasculature, including arterial occlusion, dissection, and pseudoaneurysm (Taneichi et al., 2005; Buerke et al., 2007; Yang et al., 2008; Tan et al., 2009). Furthermore, the use of MRA in practice suggests that the imaging approach may also have an influence on clinical decision-making and intervention choices where cervical pathology has been detected (Jacob et al., 2016). However, to promote wider use of MRA in practice, there is a need to evaluate diagnostic accuracy in comparison with established imaging modalities, including CTA.

### **Current debates and gaps in the knowledge base**

Despite the potential advantages of the MRA approach to imaging soft tissue and associated trauma in the neck compared to CTA, there remain important considerations to using this approach widely in practice. Firstly, there is a need for clarity regarding the comparable diagnostic accuracy of CTA and MRA in this context, ideally demonstrated through head-to-head studies (Patel et al., 2012). However, imaging outcomes based on discrimination of anatomical features of injury alone may not be sufficient to recommend one technique over another, particularly if artefactual data may be more common with one modality, potentially complicating diagnosis of injuries. Furthermore, sensitivity and specificity of the imaging strategies need to be compared, with the use of a clear gold standard approach as a baseline for comparison of these strategies (Eusebi, 2013). As CTA is considered a gold standard technique in the literature, direct comparison of the value of MRA can be considered against CTA, along with the potential added value of sequential CTA and MRA imaging (Hagspiel et al., 2015). Therefore, a robust approach is needed to determine the optimal imaging strategy in terms of anatomical visualisation and diagnostic accuracy.

Practical issues regarding imaging also need to be considered, particularly in light of the costs and time required to obtain MRA imaging assessments in a trauma context (Patel et al., 2012). The feasibility of the approach should be balanced with the potential benefits in terms of imaging quality, potential to identify neurological and vascular damage in detail, and the lack of ionising radiation associated with the modality (Greenspan and Beltran, 2020). Consideration of other practical features of imaging within a trauma context also need to be considered to ensure the application of theoretical findings to the practice setting, including the contraindications for CT and MR imaging and

aspects of the imaging protocols that may be used to optimise patient assessment. Furthermore, the identification of vascular injuries alone may be valuable, but unless these injuries require intervention or have marked clinical significance, their detection may not add to the assessment process and could delay management of other trauma-related injuries (Dunn et al., 2020). There is a need to ensure that all imaging studies are therefore aligned with the wider aim of managing trauma and play a key role in assessment without delaying other assessments or interventions. Hence, there is a need not only to evaluate diagnostic accuracy of these modalities in a comparative manner but also to establish the practical benefits and drawbacks of both, which may determine uptake among emergency practitioners (Greenspan and Beltran, 2020).

### **Justification for study**

The evidence gaps provide an important focus for the present paper, namely the need to improve the knowledge base and provide a clear evaluation of data to provide an opportunity for promoting evidence-based practice. Imaging strategies for cervical vascular injuries have been recognised as playing an important role in the diagnosis of injuries and can facilitate the use of endovascular techniques and selective non-surgical management that have been shown to have high efficacy and lower rates of complications than surgical management (Seth et al., 2013). However, for these imaging strategies to guide interventions effectively, there is a need for clear evaluation of the diagnostic accuracy of these modalities and an appreciation of contemporary evidence to take into account advances in technology for both CT and MR imaging approaches. The evaluation of the comparable diagnostic accuracy of these strategies can provide an important guide to practitioners in radiography, radiology and emergency department settings, all of whom play a key role in facilitating the management of patients experiencing acute trauma and traumatic cervical injury (Greenspan and Beltran, 2020).

Evidence-based practice forms a cornerstone of contemporary trauma management and the use of imaging should be subject to the rigorous evaluation of the evidence base to guide application in trauma contexts (Beckmann et al., 2019; Long et al., 2020). Debates over the need for focused imaging on specific anatomical sites, versus the value of whole-body imaging in trauma contexts have been noted in the literature (Long et al., 2020). Therefore, the value of the CTA approach and/or the MRA approach should be considered within the need for anatomically focused evaluation of traumatic injury in the cervical region. While both modalities may have value in practice, the need for evidence-based assessment has the potential to optimise not only the diagnostic accuracy of

assessments, but also to optimise wider practice and trauma management (Merrill et al., 2020).

## Conclusion and aims

This chapter provides an insight into the importance of evaluating the diagnostic accuracy of CTA and MRA for cervical vascular injury secondary to trauma. While CTA is commonly used in practice and represents a gold standard technique, the advantages of MRA need to be considered in the context of improving diagnosis and management of this complex condition. There is a need to compare the diagnostic accuracy of CTA and MRA to fundamentally determine the potential for MRA to serve as an alternative or replacement for CTA in this context, in order to guide best practice.

The findings of this chapter highlighted key gaps in knowledge regarding the optimal imaging strategy in patients with potential cervical vascular injury following trauma. While the use of CTA in this context is common in practice, there is uncertainty over the potential for MRA to replace or serve as a valid and reliable alternative to CTA for diagnosing cervical vascular injury. This is an important issue, as the use of imaging strategies with a high level of diagnostic accuracy can facilitate clear diagnosis of cervical vascular injury, as well as facilitating rapid and accurate assessment and management decisions in the context of trauma.

The review question is as follows: is MRA more accurate in diagnosing cervical vascular injury in trauma patients than CTA? To answer this question, the following objectives were defined for this review:

- To evaluate the diagnostic accuracy of CTA for cervical vascular injury in trauma patients
- To compare the diagnostic accuracy of MRA with CTA in this context
- To evaluate the practical and clinical implications of using CTA or MRA for cervical vascular injury assessment in trauma patients

## Methodology

### Rationale and approach

The aim and objectives defined in the previous chapter focus on a clear comparison of the diagnostic accuracy of two imaging modalities. Diagnostic imaging study comparisons should be based on quantitative data sets, as quantitative data provide an insight into objective, measurable outcomes related to a specific outcome (Cronin et al., 2018). This contrast with the use of qualitative data, which is generally more valuable in appreciating experiences or subjective

aspects of phenomena in practice, without providing objective evaluations that can inform a comparison of imaging modalities (Mills et al., 2015). Hence, a quantitative approach was employed in the present analysis in order to address the aim and objectives defined above.

Numerous research approaches may be used to perform a quantitative comparison of diagnostic accuracy of imaging modalities, including both primary and secondary research (Blankenbaker, 2016). While primary research, which involves a novel study design and collection of data from participants, can be valuable in this regard, it was not considered feasible given the time constraints of a dissertation and the limitations on data collection presented by the COVID-19 pandemic. In contrast, secondary research methods rely on published data and literature, allowing for an analysis and synthesis of the existing knowledge base, without the need for primary data collection (Dawson, 2019). This approach was used in this instance, as it not only provided a feasible strategy compared to primary research but allowed for analysis of a potentially large body of literature, while providing a synthesis of the published literature to date (Remler and Van Ryzin, 2014). This is useful as it provides an opportunity to compare and contrast literature and to perform an overall analysis of the evidence to date, providing a basis for summarising knowledge in the field and remaining gaps in the evidence base. Various approaches to secondary research have been reported (Bowling, 2014) but the literature review method is considered the most common in healthcare literature (Garrard, 2020). Specifically, the systematic literature review (SLR) is considered a gold standard approach to literature appraisal, due to the adoption of clear criteria for identifying, analysing and synthesising literature, minimising the risk of bias in these processes (Bettany-Saltikov, 2012). Therefore, the remainder of this chapter provides a detailed discussion of the SLR method as applied to the defined review question, aim and objectives.

## Search strategy

Multiple databases were used in the search strategy in order to maximise the number of relevant studies for inclusion in the review (Bramer et al., 2017). Combinations of databases containing healthcare-related, peer-reviewed literature has been advocated in the wider literature, providing an opportunity to overcome the indexing and search limitations of individual databases (Aagaard et al., 2016). The CINAHL, Embase, and Medline databases were included in this review, as this combination has been shown to provide a substantial body of literature in the context of diagnostic accuracy and imaging studies (Tanon et al., 2010; Kim et al., 2018).

Key search terms were identified based on a number of methods. Firstly, the population-intervention-comparison-outcomes (PICO) framework was used to define the review question and to identify key criteria for search term selection (Aveyard, 2014). This framework is presented in Table 2. The PICO structure reflects a focus on adult patients who have experienced traumatic injury, the evaluation of MRA and CTA and the key outcomes linked to diagnostic accuracy assessments, as noted in the wider literature (Cohen et al., 2017). The search terms for the search strategy were derived using the PICO structure, with key terms selected based on evaluation of ‘key words’ within articles used in the background section of the review and synonyms generated by the reviewer (Aromataris and Riitano, 2014). Search terms were also developed from the Medical Subject Headings (MeSH) terminology used in the Medline database, which provides a structured approach to indexing key words relating to specific clinical topics or conditions (Kable et al., 2012). Search terms were combined using Boolean operators (e.g. AND, OR) which allows for optimal combination of terms and efficiency in the search process (Peters, 2015). Additional search tools were also considered, including truncation (\*) of search terms and accommodation of alternative spellings (\$), both of which allowed for maximisation of the identification of relevant studies across international literature, although were not necessary based on the terms selected (Table 3).

**Table 2. PICO criteria**

PICO criteria	Definition
Population	Adults with cervical vascular injury associated with trauma
Intervention	Computed tomography angiography
Comparison	Magnetic resonance angiography
Outcomes	Diagnostic accuracy

**Table 3. Search terms**

PICO criteria	Search terms and strategy
Population	“vascular injury” AND “cervical” OR “cerebrovascular injury” AND “blunt” OR “penetrating” OR “blunt cerebrovascular injury” OR “BCVI” OR “vertebral artery injury” OR “VAI” OR “carotid artery injury” OR “CAI” OR “dissection”
Intervention	AND “computed tomography angiography” OR “CTA”
Comparison	AND “magnetic resonance angiography” OR “MRA”
Outcomes	AND “diagnostic accuracy” OR “sensitivity” OR “specificity” OR “predictive value”

Delimiters within the search databases were used to further refine the search process and to apply the inclusion and exclusion criteria defined in Table 4. Delimiters included a focus on human studies, the date range of published studies, and selection of English language publications (Porritt et al., 2014). These criteria

were important in ensuring a contemporary data set for analysis (reflective of the most recent practice standards and technology), maximising relevance of studies to human/clinical contexts, and ensuring that translation was not needed, which is costly and may potentially introduce errors into the data set (Jesson et al., 2011). Other inclusion and exclusion criteria are noted in Table 4 and highlight the focus on primary, quantitative studies related to the PICO criteria.

**Table 4. Inclusion and exclusion criteria.**

Inclusion criteria	Exclusion criteria	Justification
English language studies	Non-English language studies	Precludes the need for translation
Human studies	Laboratory or animal studies	Greater relevance to clinical care
Studies published 2011-2021	Studies published prior to 2011	Contemporary literature is more likely to reflect current practice and imaging protocols/technology
Primary research studies	Secondary studies	Secondary studies may be biased in their interpretation
Studies reporting diagnostic accuracy outcomes	Studies without any consideration of diagnostic accuracy	Diagnostic accuracy outcomes are crucial in comparing the performance of CT and MRA

Of note only primary studies were included to avoid the risks of including secondary research (which may have bias introduced by authors interpreting data), while specific types of study were preferred to align the review with evidence-based practice standards (Jesson et al., 2011). The hierarchy of evidence (Ingham-Broomfield, 2016) is a conceptual model that illustrates the methodological design of studies of greatest relevance to evidence-based practice, based on bias and other factors (Creswell and Creswell, 2017). Within the context of diagnostic accuracy studies, methodologies of relevance to the evaluation of evidence-based imaging practice may be further limited, with a focus on experimental methods (randomised controlled trial) and non-experimental methods (cross-sectional, cohort and case-control studies) (Karkada, 2015). Therefore, the review only included these study designs, while case studies and other methodologies were excluded to maintain a focus on high-quality evidence (Elamin and Montori, 2012).

An example of the search strategy applied to the PubMed interface, with specific isolation of Medline database results, is presented in Figure 1. Following the search strategy, a formal process was used to refine the studies and ensure relevance for inclusion in the final review data set (Moher et al., 2015). The preferred reporting items for systematic reviews and meta-analyses (PRISMA) statement was used to guide this process, as this is widely used and recommended in SLRs (Moher et al., 2015). The PRISMA refinement stages included amalgamation of search findings across all databases (with data management

facilitated by Mendely software) and exclusion of duplicate entries (Stovold et al., 2014). A series of refinement stages were then completed based on analysis of the study titles, abstracts and full-text versions, with comparison of the study content to the defined inclusion and exclusion criteria. This led to exclusion of irrelevant articles and the selection of the final review data set (Figure 2).

Figure 1. Screenshots of search results in the Medline database (via PubMed interface)

The screenshot shows the PubMed.gov search interface. The search query is 'cervical vascular injury imaging'. The results are sorted by 'Most recent' and show 554 results. The interface includes filters for 'MY NCBI FILTERS', 'RESULTS BY YEAR' (with a bar chart showing results from 2011 to 2021), 'TEXT AVAILABILITY' (Abstract, Free full text, Full text), 'ARTICLE ATTRIBUTE' (Associated data), 'ARTICLE TYPE', 'ARTICLE TYPE' (Books and Documents, Clinical Trial, Meta-Analysis, Randomized Controlled Trial, Review, Systematic Review), 'PUBLICATION DATE' (1 year, 5 years, 10 years, Custom Range), 'LANGUAGE' (English), and 'SPECIES' (Humans). The search results list several articles, including:

- 1 A Rare Case of Intra-articular Osteochondroma of the Femoral Neck: A Case Report.**  
Cite: Hammad Y, Saleh HAA, Aburumman IF, Balasim M, Al-Hyari MI, Al-Ajlouni J. J Orthop Case Rep. 2021;11(1):91-96. doi: 10.13107/jocr.2021v11.i01.1978. PMID: 34141651. **Free PMC article.**  
The presentation of such rare cases varies according to its site and mass effect, which may compress the adjacent nerves, tendon, or **vascular** structures. The femoral **neck** OC carries a higher risk of femoral head **vascular injury** and necrosis, as well as ...
- 2 Mind the gap: life-threatening retropharyngeal haematoma resulting in acute airway obstruction following blunt trauma by closing train carriage doors.**  
Cite: Patel SV, Reza A, Rice SR. BJR Case Rep. 2021 Apr 21;7(3):20200190. doi: 10.1259/bjrcr.20200190. eCollection 2021 May 1. PMID: 34131503. **Free PMC article.**  
Delayed life-threatening airway obstruction due to venous **injury** following blunt, non-penetrative trauma to the **neck**. A rare case of rapid force, blunt trauma by closing train carriage doors, leading to **injury** to the left internal jugular vein, subsequent ret ...
- 3 Magnetic resonance imaging findings following button battery ingestion.**  
Cite: Grey NEO, Malone LJ, Miller AL, Carroll HF, Khalaf RT, Kramer RE, Browne LP. Pediatr Radiol. 2021 Jun 1. doi: 10.1007/s00247-021-05085-w. Online ahead of print. PMID: 34075452  
OBJECTIVE: Our goal was to review MRI/MR angiography **imaging** in button battery ingestion cases and compare with other **imaging**, clinical data and outcomes in these patients. ...Severe complications were found in 48% of patients (11/23), including esophageal perforat ...
- 4 Proximity of the middle meningeal artery and maxillary artery to the mandibular head and mandibular neck as revealed by three-dimensional time-of-flight magnetic resonance angiography.**  
Cite: Schöneck D, Ferrari R, Ebner J, Blumer M, Lanzer M, Gander T. Oral Maxillofac Surg. 2021 May 23. doi: 10.1007/s10006-021-00960-0. Online ahead of print. PMID: 34024006  
PURPOSE: The close topographic relationship between **vascular** and osseous structures in the condylar and subcondylar region and marked variability in the arterial course has been revealed by both **imaging** and cadaveric studies. ...Extensive surgical experience and the ...
- 5 Computed Tomography Angiography for Aero-digestive Injuries in Penetrating Neck Trauma: A Systematic Review.**  
Cite: Paladino L, Baron BJ, Shan G, Sinert R. Acad Emerg Med. 2021 May 21. doi: 10.1111/acem.14298. Online ahead of print. PMID: 34021515  
OBJECTIVES: Management of hemodynamically stable patients with penetrating **neck** trauma (PNT) has evolved in recent years with improvements in **imaging** technology. Computed Tomography Angiography (CTA) encompassing all zones of the **neck** has become part of the s ...

Reset all filters

- Aberrant internal carotid artery in the oropharynx space poses a life-threatening risk of surgery.**  
6  
Cite Huang S, Li J, He T, Wang Y.  
Surg Radiol Anat. 2021 May 21. doi: 10.1007/s00276-021-02771-0. Online ahead of print.  
Share PMID: 34021391  
METHODS AND RESULTS: We report two different pathologies of retropharyngeal ICAs, which presented with otolaryngological symptoms. Case 1 Retropharyngeal right ICA. The vessel's minimum distance to the pharyngeal wall was 1 mm (very high risk of **vascular injury** ...
- Traumatic chylothorax: a dilemma to surgeons and interventionists.**  
7  
Cite Dar PMUD, Gamanagatti S, Priyadarshini P, Kumar S.  
BMJ Case Rep. 2021 May 21;14(5):e238961. doi: 10.1136/bcr-2020-238961.  
Share PMID: 34020985  
Chylothorax is generally seen due to iatrogenic **injury** to the thoracic duct during thoracic or **neck** surgery. It can also be encountered secondary to chest trauma either blunt or penetrating. ...
- Bone Mineral Density Measurements and Association With Brain Structure and Cognitive Function: The Framingham Offspring Cohort.**  
8  
Cite Stefanidou M, O'Donnell A, Himali JJ, DeCarli C, Satizabal C, Beiser AS, Seshadri S, Zaldy T.  
Alzheimer Dis Assoc Disord. 2021 May 11. doi: 10.1097/WAD.0000000000000453. Online ahead of print.  
Share PMID: 33973881  
We examine the association between BMD in the "young old" with **imaging** biomarkers of brain aging and cognitive performance. METHODS: Offspring participants (N=1905, mean age 66) of a population-based cohort who had BMD, brain **imaging** and detailed cognitive assessmen ...
- Transient global amnesia after radiofrequency catheter ablation of supraventricular tachycardia: a case report.**  
9  
Cite Sun S, Huang Q, Chen X, Liu Q, Wang C.  
Cardiovasc Diagn Ther. 2021 Apr;11(2):472-477. doi: 10.21037/cdt-20-895.  
Share PMID: 33968625 **Free PMC article.**  
Tests were performed immediately and normally including blood routine examination, liver and kidney function, electrolyte, blood glucose, thyroid function, blood coagulation function, D-dimer, myocardial **injury** markers, blood gas analysis and other hematological. There is ...
- Endoscopic Endonasal Surgery of a Large Vidian Nerve Schwannoma With Preparation for Avoiding Major Vascular Injury.**  
10  
Cite Tanaka C, Kikuchi M, Matsunaga M, Omori K, Nakagawa T.  
Cureus. 2021 Mar 31;13(3):e14230. doi: 10.7759/cureus.14230.  
Share PMID: 33959429 **Free PMC article.**  
Based on the above, we suspected a vidian nerve schwannoma, and endoscopic endonasal surgery was performed with particular attention to avoid **vascular injuries**. An endoscopic transmaxillary approach was used to expose the anterior surface of the tumor. ...Endoscopic ...
- Page 2
- A case report of cervicothoracic penetrating injury with retention of foreign body.**  
11  
Cite Hui Y, Yang X, Ma D, Yao M, Liu X, Dai Y, Huang Q, Liu T, Xu J, Li X.  
BMC Surg. 2021 May 3;21(1):232. doi: 10.1186/s12893-021-01234-y.  
Share PMID: 33941158 **Free PMC article.**  
CASE PRESENTATION: A male patient suffered from a serious **injury** caused by a thick branch that pierced through his **neck** in a traffic accident between an electric car and a tricycle carrying wood. There were also local **injuries** in the left scapular region. Aft ...

## Data analysis and synthesis

Data Extraction is defined as the process of evaluating the findings of studies on an individual basis, identifying the relevant data within those studies, and then isolating and documenting that data in a formal and consistent manner (Hart, 2018). The data extraction process should be reliable in nature, emphasising the importance of utilising a structured framework or tool for this purpose (Bettany-Saltikov, 2012). A widely used approach is a data extraction table or

form, which comprises key criteria and data that should be derived from each study and then may be completed upon reading and evaluating each study (Bryman, 2016). An example data extraction form is used in Cochrane systematic reviews and according to the Joanna Briggs Institute for evidence-based medicine (e.g. Munn et al., 2014). The key criteria (data) extracted from individual studies varies across examples in the literature but should be individualised to the review topic (Aveyard, 2014). In this instance, the focus of the review is on diagnostic accuracy of studies and therefore the key data extracted from the review were defined according to specific diagnostic accuracy features, as well as broader features of studies that highlight quality and reliability. These criteria were as follows: study author and date, study design, population studied and sample size, imaging protocol details, sensitivity, specificity, positive and negative predictive values.

Methodological quality assessment was also completed in order to support the data extraction process and provide additional insights into the quality of the data set (LoBiondo-Wood and Haber, 2017). A range of tools are available to support critical appraisal, although many are limited by their application to one specific type of study or a focus that is too broad to take into account methodological issues that apply to specific study methodologies (Schneider et al., 2016). The Critical Appraisal skills Programme (CASP) toolkit was employed for this purpose, as this toolkit contains a range of checklists (tools) that are designed to critically appraise individual study methodologies (Grove and Gray, 2018). The CASP toolkit is widely used in the context of systematic reviews, is flexible in application to a range of studies, and provides a detailed insight into the strengths and weaknesses of each study (Schneider et al., 2016). Each study underwent formal critical appraisal in order to highlight methodological issues within the study. The CASP tool is not designed to provide a numerical quality score or to provide a basis for excluding studies (Bankhead and Stevens, 2018) and therefore the critical appraisal process was used as a basis for informing wider critique of the literature following data synthesis (Boswell and Cannon, 2018).

In addition to the CASP toolkit, the QUADAS-2 instrument was also used to guide evaluation of bias in primary diagnostic imaging studies in this review, as recommended in the wider literature (Mallett et al., 2012). The QUADAS-2 instrument evaluates bias in four key domains: patient selection, index test, reference standard, and flow and timing (Whiting et al., 2011). These elements are considered within wider discussion of the quality of individual studies and the collective data set to support primary analysis with the appropriate CASP tool, allowing for further insights into sources of bias specific to primary diagnostic imaging studies. This is an important point to consider, as bias in diagnostic testing

studies may influence the relative interpretation of the value of CTA or MRA, which may influence the key results of the review.

Data Synthesis was the final stage in the review process and involves a comparison of the literature and identification of consistencies and trends across the literature. While a meta-analysis method may be used to combine and evaluate the results of quantitative studies in a robust manner (Moule et al., 2016), this was not considered feasible due to reviewer inexperience and the likely heterogeneity of the included studies (Bettany-Saltikov, 2012). An alternative approach to synthesis was employed, based on evaluation of methods used in other reviews and wider theoretical literature on the topic (Lisy and Porritt, 2016). Narrative synthesis is considered one of the most widely used and valuable approaches to synthesis in SLR contexts, outside of meta-analysis, and has the opportunity to develop a theory of the intervention or test and how this works, allows a clear synthesis of the results of studies, provides a basis for exploring relationships in the data, and allows for robustness to be assessed within the synthesis (Popay et al., 2006).

The narrative synthesis method was performed according to the framework of Campbell et al. (2020), which is defined as the synthesis without meta-analysis (SWiM) framework. This framework involves grouping studies for the synthesis, standardising and describing the synthesis methods, prioritising the key findings across studies, identifying heterogeneity, analysing methods and evaluating the certainty of evidence (Campbell et al., 2020). The narrative synthesis was therefore facilitated by reading the entirety of the included studies, identifying consistencies and trends within the literature, and then generating themes/narratives relating to core topics and findings. The reporting phase of this framework involves a structured comparison of the findings of studies, along with reliability and critical appraisal data (Campbell et al., 2020). This framework is beneficial in that it takes into account a range of important factors linked to critical appraisal and is linked to the PRISMA criteria used in this review, aligning the review elements (Campbell et al., 2020).

## Findings

### Search Finding

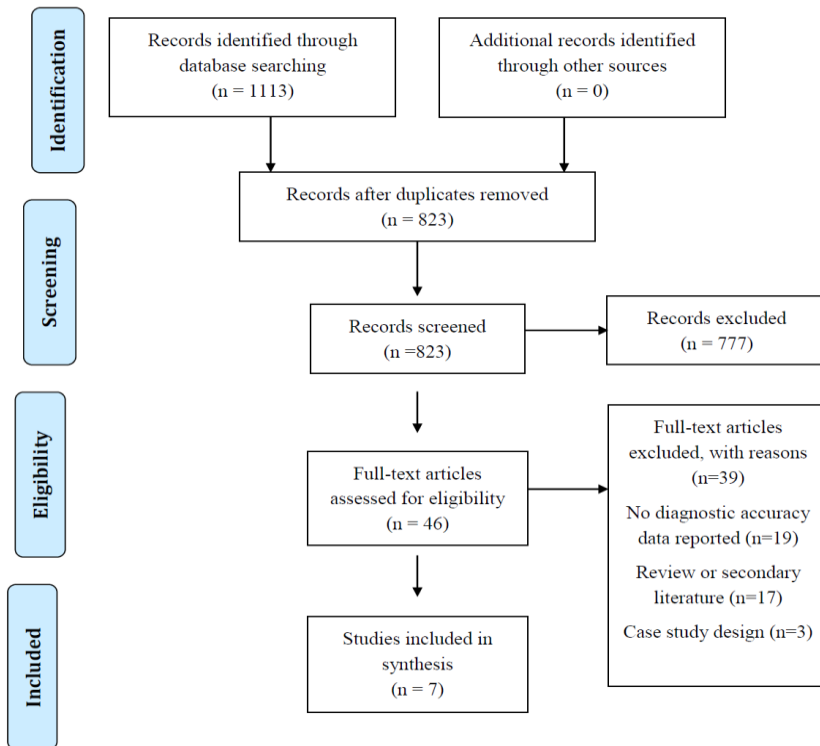
The findings of the search strategy led to identification of 823 unique studies, as shown in the PRISMA flow diagram (Figure 2). These studies were refined, as defined in the previous chapter. Seven studies were suitable for inclusion in the final review data set. A lack of focus on the PICO criteria, failure of studies to report outcomes relating to diagnostic accuracy, and the adoption of secondary research methods were the study exclusion reasons. Importantly, there was a paucity of literature reflecting the use of MRA in the context of blunt or penetrating cerebrovascular injury or other forms of cervical vascular trauma

within the body of literature. Five of the included studies focused on evaluating the diagnostic accuracy of CTA (DiCocco et al., 2011; Paulus et al., 2014; Shahn et al., 2016; Grandhi et al., 2017; Ares et al., 2019), while the remaining two studies evaluated the diagnostic accuracy of MRA (Takano et al., 2013; Vranic et al., 2020).

### Summary of study quality and characteristics

The findings of formal critical appraisal of the studies using the CASP toolkit are shown in Table 5 and the findings of the QUADAS-2 bias assessment are summarised in Table 6. The summary of the data extraction process is presented in Table 7. The critical appraisal findings generally established the data set as including moderate-to-high quality evidence, based on the strictness of the methods used and the detail of reporting within the studies, according to CASP criteria. Some key methodological limitations were evident across the literature, however. Similarly, heterogeneity was evident across the literature, which included some important differences in patient characteristics, imaging strategies employed, and outcomes assessed.

Figure 2. PRISMA flow diagram



**Table 5. CASP critical appraisal findings.** The CASP diagnostic checklist was used to inform critical appraisal of all seven included studies. The response to appraisal are noted in the table, according to the following key: yes, Y; No, N; uncertain, ?.

Question	Dicocco et al., (2011)	Takano et al. (2013)	Paulus et al., (2014)	Shahan et al. (2016)	Grandhi et al. (2017)	Ares et al. (2019)	Vranic et al. (2020)
Clear question?	Y	Y	Y	Y	Y	Y	Y
Reference standard?	Y	Y	Y	Y	Y	Y	?
Diagnostic test and reference standard for all patients?	Y	N	Y	Y	Y	Y	N
Influence of reference standard?	N	?	N	?	N	N	?
Disease status described?	Y	Y	Y	Y	Y	Y	Y
Detailed test information?	N	Y	N	Y	Y	Y	Y
Clear results?	Y	Y	Y	Y	Y	Y	Y
Certainty of results?	Y	Y	Y	Y	Y	Y	Y
Local application of findings?	Y	?	Y	Y	Y	Y	?
Local application of tests?	Y	?	Y	Y	Y	Y	?
All important outcomes considered?	?	?	?	?	?	?	?
Impact of test in local population?	?	?	?	?	?	?	?

**Table 6. QUADAS-2 bias assessment findings.** Risk of bias for each of the four criteria are noted as high, low or unclear.

Author and date	Patient selection	Index test	Reference standard	Flow and timing
DiCocco et al. (2011)	Low	Low	Low	Unclear
Takano et al. (2013)	Unclear	Low	Low	Unclear
Paulus et al. (2014)	Low	Low	Unclear	Low
Shahan et al. (2016)	Low	Low	Low	High
Grandhi et al. (2017)	Low	Low	Low	High
Ares et al. (2019)	Low	Low	Unclear	Low
Vranic et al. (2020)	Low	Low	Low	High
DiCocco et al. (2011)	Low	Low	Low	Low

**Table 7. Summary of study characteristics.** CTA, computed tomography angiography; DSA, digital subtraction angiography; MRA, magnetic resonance imaging; NPV, negative predictive value; NR, not reported; positive predictive value; VWI, vessel wall imaging

Study author and date	Design	Imaging modalities	Reference standard	Sensitivity	Specificity	Other findings
DiCocco et al. (2011)	Diagnostic accuracy study	32-slice CTA	DSA	51%	97%	PPV 43%, NPV 98%, diagnostic accuracy 95%
Takano et al. (2013)	Diagnostic accuracy study	MRA, MR imaging	CTA/DSA	NR	NR	3/16 haematomas missed with MRA, a 12.5% failure to distinguish intramural haematomas, and a 50% rate of detection of characteristic imaging signs
Paulus et al. (2014)	Diagnostic accuracy study	64-slice CTA	DSA	68%	92%	PPV 36.2%, NPV 97.5%
Shahan et al. (2016)	Diagnostic accuracy study	CTA	DSA	NR	55%	PPV 55%
Grandhi et al. (2017)	Diagnostic accuracy study	CTA	DSA	52.6%	52.6%	PPV 53%
Ares et al. (2019)	Diagnostic accuracy study	CTA	DSA	72%	63%	NR
Vranic et al. (2020)	Diagnostic accuracy study	MRA, VWI	Expert consensus/CTA	NR	NR	82% agreement with expert consensus (VWI) versus 36% (CTA); MRA agreed with consensus for low grade lesions

he studies showed a moderate degree of heterogeneity based on the characteristics of the participants included and the nature or protocols used for CTA or MRA within the context of cervical vascular imaging. The characteristics of the patients included in the studies showed variation based on the specific injury

assessed. While all studies included consecutive patients or purposively identified patients based on records, with no evidence of inappropriate exclusions, the specific focus on certain injuries may influence patient selection criteria and comparability, an important potential point of bias in QUADAS-2 criteria. For instance, blunt cerebrovascular injury was the focus of the studies by DiCocco et al. (2011), Paulus et al. (2014), Shahan et al. (2016) and Grandhi et al. (2017); these studies all evaluated the carotid artery and vertebral artery as potential sites of injury during a trauma situation. Similarly, for MRA analysis, the study by Vranic et al. (2020) evaluated all instances of blunt cerebrovascular injury following acute trauma, with a focus on carotid and vertebral arteries. Ares et al. (2019) focused on penetrating injury to the cervical region, rather than blunt injury, although the focus remained on the same vessels (i.e., carotid, and vertebral vasculature). The study by Takano et al. (2013) focused exclusively on imaging of intramural haematomas in vertebral arteries following dissection, without consideration of other lesions or sites of injury. Therefore, it should be noted that differences in sites of injury and types of injury (blunt or penetrating) may preclude comparability of the studies to some degree, including generalisability of findings. In addition to the injuries assessed, there was some variability in the patient characteristics related to severity or nature of the injury sustained. Blunt and penetrating injuries were noted in studies, as suggested above, while the severity of the injury may have been a source of heterogeneity. Certainly, Vranic et al. (2020) used an assessment process where CTA screening was performed, and subsequent analysis justified using expert consensus and MRA where findings were suspicious for carotid artery lesions. Therefore, this group of patients may represent cases where lesions posed a specific diagnostic challenge due to the need for expert consensus and MRA where equivocal findings were seen on CTA. Similarly, the studies by Shahn et al. (2016) and Grandhi et al. (2017) included protocols where lesions that were equivocal on CTA were confirmed using DSA. Therefore, these studies may have only included lesions that posed diagnostic challenges, representing a unique group compared to patients routinely screened for pathology, as in other studies (DiCocco et al., 2011; Paulus et al., 2014).

The protocols used in the studies, including characteristics of the CTA or MRA approaches varied to a large extent. The details of the study protocols were often limited in the included studies, but the main features of the technology and the imaging strategy used for CTA tended to vary according to the number of channels (or slices) included in the imaging strategy (e.g., 32-channel versus 64-channel), reflecting changes to imaging technology over time (DiCocco et al., 2011; Paulus et al., 2014). While the use of DSA was typically a primary imaging study, against which subsequent CTA or MRA findings were compared, the study

by Shahan et al. (2016) used a new protocol where CTA was the primary modality and DSA was only employed in equivocal cases. The same protocol was employed by Grandhi et al. (2017), which reflected institutional use of CTA as a primary imaging modality and the use of DSA as a confirmatory diagnostic test only. Similarly, where a suspected cervical vascular injury was evident on CTA in the study by Vranic et al. (2020), this was an indication for subsequent MRA assessment. Therefore, over time (from 2011 to 2020, when studies were published) the use of CTA became a primary imaging strategy and preferred screening approach rather than DSA.

The outcomes reported across the studies, related to diagnostic accuracy, were prone to some variation. Typical outcomes of sensitivity and specificity compared to a reference standard were noted in most studies, often with the reporting of positive or negative predictive values and other criteria (DiCocco et al., 2011; Paulus et al., 2014; Ares et al., 2019). However, some studies focused on reporting false-positive rates of injury detection or specific imaging findings that were indicative of accuracy, including inter-rater agreement of findings and confirmation of findings using other imaging studies (Takano et al., 2013; Shahan et al., 2016; Grandhi et al., 2017; Vranic et al., 2020). These differences in reported outcomes represented important factors to consider during the synthesis of the literature in the following section of this chapter.

The use of reference standards in the studies was assessed using the QUADAS-2 tool, noting that the use of these standards varied to a degree, although there was a consistency in the use of DSA as a general gold standard reference, which reflects contemporary guidance and consensus on imaging of cervical vascular injury (Ares et al., 2019). The study by Takano et al. (2013) evaluated a range of MR imaging strategies, including MRA, and used both DSA and CTA as reference standards. Index tests were all performed with a low risk of bias, with pre-specified criteria for determining outcomes.

Therefore, while this study included patients with MRA and CTA assessment in some instances, the use of DSA and/or CTA as a reference standard excluded evaluation of CTA and MRA against the reference standard of DSA. Vranic et al. (2020) used a complex assessment process, whereby CTA was completed along with MRA and adjunctive MR imaging (vessel wall imaging) in patients with suspected lesions affecting the carotid arteries. The findings of the MR assessments were not only compared with the CTA findings but were evaluated by two expert neuroradiologists, who provided a consensus on the diagnosis (presence of a traumatic lesion). Therefore, expert consensus agreement was considered the primary method for evaluating the diagnostic accuracy of the imaging strategies. The flow and timing of tests (CTA and MRA) were all

appropriate according to QUADAS-2 criteria, although there was a difference in the timing of the use of MRA or CTA in the study by Vranic et al. (2020) (where MRA was only used in equivocal CTA cases), while Shahan et al. (2016) and Grandhi et al. (2017) initially used CTA imaging and then employed DSA in equivocal cases.

Although the characteristics of the included studies showed some heterogeneity, key themes were derived from the literature and were used to inform the narrative synthesis presented for the remainder of this chapter. Results of individual studies are presented collectively within these themes, supported by critique derived from CASP and QUADAS-2 assessment processes.

### **Theme one: Diagnostic accuracy of CTA for cervical vascular injury**

The first theme considers the diagnostic accuracy data for CTA when used in the context of cervical trauma. This theme provides an insight into the findings from five studies that focused on CTA use in practice, with a structure reflecting the reported outcomes related to diagnostic accuracy (sensitivity, specificity, etc) and considered in the context of the specific pathology or injury detected in the trauma context.

The sensitivity of CTA varied across studies, which reflects heterogeneity in the imaging protocol used to complete CTA to a large extent. DiCocco et al. (2011) found that 32-channels CTA was associated with an overall sensitivity of 51% in 684 patients with cervical trauma when compared with the reference standard of DSA. This sensitivity was largely consistent across the different types of vessels assessed, with a 50% sensitivity for carotid vessels and 53% sensitivity for vertebral vessels. Even when poor quality imaging studies (due to patient movement or poor contrast bous or timing) were considered and excluded from the final data set. DiCocco et al. (2011) noted that the sensitivity only improved from 51% to 52%, suggesting that imaging quality had little impact on diagnostic sensitivity. A similar study (Paulus et al., 2014) using 64-channel CTA compared to the DSA reference standard conducted in 594 patients found that CTA was associated with a sensitivity of 68% per vessel. More recently, the study by Ares et al. (2019) found that the sensitivity of CTA was 72% for the detection of cervical vascular injury. These findings show a trend in increased diagnostic sensitivity over time, although it should be noted that the study by Ares et al. (2019) focused on penetrating traumatic injuries and not blunt injuries, as seen in the study by DiCocco et al. (2011) and Paulus et al. (2014), and therefore comparability may be limited to some extent. Furthermore, the sensitivity rate reported in the study by Grandhi et al. (2017) was 52.6% for the use of CTA compared with DSA in

assessment of blunt cervical vasculature injury, suggesting that imaging technology improvements over time may not fully account for improvements in sensitivity. In this study, the authors noted that sensitivity varied according to the grade of lesion and the nature of the injury and/or presence of concurrent injuries. This suggested that specific clinical features may have accounted for the low sensitivity, including a high number of complex skull fractures or low-grade lesions; these modifying factors are considered further in theme three.

Specificity of the CTA examination was reported in several studies, contrasting with the trends seen with sensitivity results over time. DiCocco et al. (2011) found a specificity of 97% for the use CTA when applied to both carotid and vertebral vessels in the context of blunt trauma. The specificity of CTA was also high in the study by Paulus et al. (2014), with a value of 92%, which applied to the assessment of blunt cervical trauma. In contrast, Ares et al. (2019) found a specificity for CTA of 63% for the diagnosis of penetrating cervical trauma when compared with DSA. The false-positive rate was reported in several studies assessing the use of CTA in cervical vascular trauma. A rate of 45% was noted in the study by Shahan et al. (2016), which suggests a specificity of only 55%, which is considerably lower than the value of 92% reported for the same imaging approach (64-slice CTA) in the study by Paulus et al. (2014). False-positives were analysed in detail in the study by Grandhi et al. (2017), which included 140 patients with 156 blunt cerebrovascular injuries to the carotid and/or vertebral vasculature. The overall false-positive rate of CTA compared to DSA was 47.4%, suggesting a specificity of only 52.6%. This specificity varied according to the grade of lesion identified and the indication for screening, issues considered further in theme three.

The positive and negative predictive values of CTA were also reported in some of the included studies (DiCocco et al., 2011; Paulus et al., 2014; Grandhi et al., 2017). The positive predictive value was 36.2% and the negative predictive value was 97.5% in the study by Paulus et al. (2014), which is comparable to the figure seen in the study by DiCocco et al. (2011), with 43% and 98% reported for positive and negative predictive values, respectively. The figures for positive predictive value were low in this study and suggested that up to 57–64% of patients diagnosed with blunt cerebrovascular injury would receive anticoagulation unnecessarily unless other imaging modalities were employed for screening/diagnosis of such injuries (DiCocco et al., 2011; Paulus et al., 2014). A slightly higher positive predictive value of 55% was seen with the use of CTA for the diagnosis of blunt cerebrovascular injury in the study by Shahan et al. (2016). This study used 64-channel CTA, as with the study by Paulus et al. (2014). This is similar to the result reported by Grandhi et al. (2017), where a positive predictive

value of 53% was seen for CTSA relative to DSA reference imaging. However, in this study the positive predictive value varied across lesion grades and the indication for screening, matching the sensitivity and specificity findings of the study.

Overall, this theme suggests that as technology has advanced in the use of CTA for the assessment of cervical trauma, the diagnostic accuracy of the technique has also improved relative to the use of DSA as a reference imaging strategy. The use of 64-channel CTA has demonstrated how technological advances (from 32-channel CTA) can produce improvements in sensitivity and specificity for detecting injuries to cervical vasculature. Overall, sensitivity ranged from 51–72% and specificity ranged from 63–97% for the use of CTA in diagnosing cervical vascular injury. However, the heterogeneity of the studies and the context in which CTA was performed (i.e., blunt versus penetrating trauma) need to be considered when considering these findings. DiCocco et al. (2011) reported a diagnostic accuracy of CTA for blunt vessel diagnosis of 95%, based on now outdated imaging technology, generally suggesting that CTA has a high diagnostic accuracy in this context.

## **Theme two: Diagnostic accuracy of MRA for cervical vascular injury**

Only two studies included in the review provided an assessment of the diagnostic accuracy of MRA in the context of cervical trauma. However, these studies differed in their approach significantly and therefore careful analysis is required to extract the key data on diagnostic accuracy specific to MRA for both studies, while considering heterogeneity in the methods employed and outcomes measured. Takano et al. (2013) evaluated the use of three different MR imaging strategies, using both DSA and CTA as reference standards in the context of intramural haematoma diagnosis in patients with traumatic vertebral artery dissection. The three MR imaging modalities were MRA, axial spin echo T1-weighted images (SE-T1WI) and three-dimensional black blood T1-weighted imaging (3D-BB-T1WI). The study by Vranic et al. (2020) primarily focused on the diagnostic utility of MR imaging using a vessel wall imaging (VWI) protocol. However, this study included a comparison of the VWI findings with the reference standard of CTA and the imaging findings noted on MRA, which was completed as a part of the VWI process. Therefore, while MRA was not the focus of the study, the findings do provide an insight into the role of MRA in cervical vascular injury assessment.

The study by Vranic et al. (2020) focused on blunt cerebrovascular injury in acute trauma patients (n=10; 40 cervical arteries assessed). Suspected injury

following CTA led to subsequent analysis using VWI, with a protocol containing MRA assessment in addition to the MR imaging linked to vessel wall assessment. The VWI process was appraised in comparison to the initial CTA findings and then to an expert consensus review completed by two neuroradiologists. Overall, the findings suggested that out of 18 vascular lesions identified as suspicious, six lesions were considered true vascular injuries based on expert consensus review. There was an 82% agreement between expert consensus review and the findings of VWI assessment, while agreement between CTA and expert consensus was only 36% in this context. When VWI, MRA and CTA findings were compared there was a high level of agreement reported across studies, with perfect agreement in findings for more severe injuries. Indeed, the diagnostic accuracy of VWI was not superior to MRA for higher grade lesions but was superior for lower grade lesions when compared with expert consensus and CTA findings.

Takano et al. (2013) found that MRA was associated with a risk of missed intramural haematoma to a greater degree than other MR imaging studies and when compared with CTA and DSA reference standards. This equated to 3/16 haematomas missed with MRA, a 12.5% rate of failure to distinguish intramural haematomas from intraluminal signals, and a 50% rate of detection of characteristic imaging signs representing haematoma (e.g., crescent shape). The findings are therefore more complex to interpret than standard sensitivity and specificity determinations, although the findings indicate that imaging quality for intramural haematoma detection with MRA was suboptimal versus all other MR and non-MR imaging modalities, while the diagnostic accuracy was lower than the reference standards, including DSA and CTA.

In summary, while this theme provides an insight into the diagnostic accuracy of MRA in the context of cervical vascular injury associated with trauma, the methodological approaches used in the two included studies and the outcomes reported limit the assessment of the clinical utility of MRA in practice. Indeed, sensitivity and specificity of the technique are not reported, while other diagnostic accuracy outcomes (e.g., positive predictive value) are not reported. Estimations of diagnostic accuracy based on small patient numbers and assessment compared to reference standards and other MR imaging approaches do suggest limitations to the use of MRA in practice, however.

### **Theme three: Factors influencing diagnostic accuracy of CTA or MRA**

The final theme considers the factors that modify or potentially influence the diagnostic accuracy of CTA or MRA in the practice setting, as well as influencing the feasibility of these procedures in practice. Specifically, the factors linked to variability in diagnostic accuracy for these modalities included the

characteristics or technology used for the imaging studies. The nature of the clinical lesions (i.e., injury severity) and the location of the injury within the cervical vasculature.

The first factor influencing the diagnostic accuracy of the interventions was the technology used for CTA or MRA. For CTA, the number of channels or slices obtained in imaging studies was a key factor influencing the diagnostic accuracy of outcomes, as demonstrated when comparing the use of 32-channel and 64-channel approaches in the studies by DiCocco et al. (2011) and Paulus et al. (2014), respectively. A sensitivity increases from 51% to 68% was noted from the use of 32-channel and 64-channel CTA in a similar patient population (DiCocco et al., 2011; Paulus et al., 2014). DiCocco et al. (2011) noted that previous work by the same group suggested that 16-channel CTA was associated with a lower sensitivity for the detection of blunt cerebrovascular injury diagnosis, suggesting that technology may be a key factor in promoting diagnostic accuracy. However, caution is needed in interpreting these findings, as both imaging approaches were not directly compared in the same test setting, while other studies did not repeat these findings. Furthermore, in addition to technological advances, other factors may have influenced the diagnostic accuracy of CTA over time, including increasing expertise and familiarity with the use of CTA among radiological staff (Paulus et al., 2014).

As noted previously, false-negative results for CTA in the study by Paulus et al. (2014) were commonly linked to carotid artery injuries (34/52), while a smaller percentage of false-negatives were linked to vertebral artery injuries (18/52), suggesting that the specific vessel assessed may influence diagnostic accuracy to some degree. However, the findings of Shahan et al. (2016) found that the rate of false-positives associated with CTA was broadly consistent across vessel site, with 42% linked to internal carotid artery injuries and 56% to vertebral artery injuries. Furthermore, DiCocco et al. (2011) found that sensitivity values were consistent across vessel types (carotid and vertebral).

The grade of injury was a more consistent factor linked to differences in the diagnostic accuracy of CTA in the published literature, although only in a few studies (Paulus et al., 2014; Shahan et al., 2016). Paulus et al. (2014) found that the majority of false-negatives were associated with low-grade injuries to carotid or vertebral arteries. Similarly, Shahan et al. (2016) noted that false-positive screening results using CTA were more common in low grade injuries (87% in the lowest grade). The study by Vranic et al. (2020) found that assessment of low-grade blunt cerebrovascular injuries was generally consistent when using CTA, MRA or VWI (an adjunct to the MRA protocol), while higher grade injuries were more likely to benefit from the additional diagnostic sensitivity of VWI, compared to both CTA

and MRA. Therefore, this study suggests that lower grade lesions may be amenable to assessment with both MRA and CTA, while higher grade lesions may benefit from additional imaging approaches.

Grandhi et al. (2017) performed a detailed analysis of the differences in sensitivity, specificity, and positive predictive values of CTA assessment across different grades of lesion identified in patients following blunt trauma. The study showed that sensitivity was 30.4% for the lowest grade of injury (grade I) and increased with the severity of the injury up to 96.8–100.0% for the highest grade lesions (IV and V). Therefore, the range of values around the mean sensitivity of 52.6% in this study was significant and largely determined by the grade of the lesion identified. This was important as the number of lesions in each grade varied considerably, with a high amount of grade I and grade IV lesions, suggesting clear potential for difference in sensitivity of the imaging tests.

Finally, some studies also suggested that additional factors may influence the diagnostic accuracy of the imaging studies. The indication for screening using CTA was also considered an influence on diagnostic accuracy in the study by Grandhi et al. (2017). This study found that the sensitivity was highest for closed head injuries with altered consciousness (80%), seat belt abrasions with associated pain (75%) and cervical spine injury through any traumatic mechanism (59.6%). However, sensitivity was reduced for vessel injury identification where skull fractures were present, including complex skull fractures (27.6%) and midface fractures (37.5%). No other study provided a detailed assessment of the role of different cervical traumas or injury features on sensitivity. However, it was suggested by the authors in the study by Paulus et al. (2014) and Shahan et al. (2016) that the presence of fractures was an impediment to imaging quality and diagnosis of injuries, though this was not formally reported in the main results.

DiCocco et al. (2011) found that gender may play a role in determining the sensitivity of the diagnostic process. The study found that the number of false negatives was higher in women compared with men, with a sensitivity of 45% in women compared with 56% for men, which was statistically significant ( $P=0.003$ ). No other studies identified differences in gender for sensitivity, however, or this finding was not explored (Paulus et al., 2014). Therefore, it is uncertain if this is a significant factor modifying or influencing diagnostic accuracy of CTA.

Due to the rareness of studies focusing on the role of MRA in cervical vascular imaging, there is limited evidence to suggest consistent modifying factors for imaging quality and diagnostic accuracy in practice. Takano et al. (2013) found that imaging quality for haematoma detection (intramural haematomas in the vertebral artery following dissection) was limited with MRA, potentially reflecting a challenging clinical context in which to use this modality. However, the study did

not compare the use of MRA for detection of other lesions or in other vessels, limiting the potential to draw this conclusion.

## Summary

This chapter provides a detailed evaluation of the literature identified using the formal search strategy. A total of seven studies were identified using the search process, with exclusion of a large body of literature due to a lack of focus on cervical trauma patients, the use of CTA or MRA in the context of evaluation of diagnostic accuracy, and the use of inappropriate methodologies. The results suggested that CTA had a sensitivity that ranged from 51–72% and a generally high specificity (97%) compared with DSA in blunt and penetrating cervical trauma contexts. This translated to a high overall diagnostic accuracy in this context. In contrast, the use of MRA was not assessed in a strong manner and sensitivity or specificity values were not reported. The diagnostic accuracy of MRA was comparable to CTA in some contexts and consistent with expert consensus in challenging diagnostic cases, although wider evaluation of formal diagnostic accuracy was lacking in the literature. Factors that potentially influence diagnostic accuracy of CTA included the severity of the injury, any concurrent injuries, and the vessel affected, although these factors were not consistent across studies. Importantly, these features were not explored in detail for MRA and overall, the comparability of diagnostic accuracy of CTA and MRA was not assessed directly in any of the included studies, limiting the potential to address the main review question. The following chapter considers these findings in detail and provides a discussion of their implications relative to wider literature and modern practice guidance.

## Discussion

### Overview of the SLR findings

This SLR was designed to meet a gap in the current knowledge base regarding the relative diagnostic accuracy of MRA and CTA in patients with suspected cervical vascular injury secondary to trauma. Seven studies were identified that met the inclusion criteria and the PICO criteria defined for the SLR, generating three themes for discussion.

The first theme explored the diagnostic accuracy of CTA in the context of cervical vascular injury. This theme found that while there was heterogeneity in studies and changes to sensitivity of CTA over time, there was a general finding that the diagnostic accuracy of CTA was high (95%) and that this reflected a high specificity and moderate or high sensitivity. Sensitivity appeared to be a key diagnostic outcome that has improved over time (DiCocco et al., 2011; Paulus et

al., 2014), while specificity remained high across the time period of the included studies (2011–2019). The second theme explored the diagnostic accuracy of MRA relative to any reference standard. This analysis was limited by the inclusion of two studies only and the lack of robust diagnostic accuracy assessment of MRA in the context of general cervical vascular injury. Indeed, assessment by Takano et al. (2013) focused on intramural haematoma diagnosis, while the assessment by Vranic et al. (2020) focused on carotid artery pathology in patients with equivocal findings on CTA. These studies are therefore hard to generalise to the cervical trauma context and may be difficult to compare in terms of diagnostic outcomes. The final theme suggested that the diagnostic accuracy of the imaging studies (particularly CTA) was influenced by several factors related to the patient and the clinical characteristics of the injury. While there was a lack of general agreement across studies for all of the potential modifying factors (e.g. gender), severity of the lesion (i.e. grade) and indication or site of the traumatic injury may all influence sensitivity of the diagnostic imaging strategy. These issues are considered further in this chapter, with reference to the wider literature, following a discussion of the key quality or methodological issues noted in the review data set.

## Overview of methodological quality

The methodological quality of studies included in a SLR can have an important bearing on the quality of that review and the strength of the conclusion that can be drawn (Phan et al., 2015). The present review included two distinct methodological quality assessment process: the CASP toolkit, which provides an overall methodology-specific assessment of quality, and the QUADAS-2 tool, which assessed bias in relation to diagnostic imaging studies specifically (Whiting et al., 2011). The CASP appraisal provided a general insight into overall methodological quality of the collective data set, suggesting that most studies were limited by the inclusion of a relatively small sample size, lack of consistent or clear recruitment data, the potential for differential exposure to treatment or imaging protocols (based on heterogeneity in severity of lesions and patient characteristics), and based on inconsistencies in reporting of diagnostic accuracy outcomes.

One important methodological challenge was the lack of clarity in how patients were assigned to imaging modalities and the risk of bias therein (Goldzweig et al., 2015). Indeed, the use of MRA, CTA or other imaging approaches may have been influenced by practitioner preferences or clinical assessment not only of the cervical region and risk of vascular injury, but also with respect to other injuries and patient features. Furthermore, local guidelines may have influenced the preferred imaging strategy and sequence of imaging studies: Shahan et al. (2016) prioritised the use of CTA according to local protocols, while

Paulus et al. (2014) utilised DSA as a primary imaging modality, with CTA used as a secondary strategy. This may influence the value and interpretation of imaging studies (particularly if other modalities may be consulted to support analysis) and may reflect differences in patient populations and injury severity, as diagnosis in equivocal cases may reflect a challenging patient group to manage effectively (Han et al., 2016).

Another methodological issue was the reporting of outcomes related to diagnostic accuracy. Only one study provided an overall summary of diagnostic accuracy (DiCocco et al., 2011), where a value of 95% was reported. Subsequent studies showed improvements in sensitivity associated with CTA imaging (Paulus et al., 2014; Shahan et al., 2016) but no overall reporting of diagnostic accuracy. There was also significant variability in the reporting of positive and negative predictive values and other features of the diagnostic accuracy of CTA. This limits the degree to which the overall accuracy of studies may be assessed in detail (Eusebi, 2013). This is particularly problematic for the use of MRA, as the studies included in this review did not provide detailed assessment of sensitivity or specificity (Takano et al., 2013; Vranic et al., 2020). This reflects the focused nature of the evaluations on specific sites of pathology (e./g. intramural haematoma) and the small number of patients included in the analyses, which limits the degree to which robust assessment of diagnostic accuracy can be completed (Whiting et al., 2011).

The bias related to diagnostic imaging assessment also reflected differences and inconsistent in the reference standard used, which is an important factor in providing a consistent evaluation of accuracy (Whiting et al., 2011). The reference standard of DSA is considered appropriate for the evaluation of cervical trauma and vascular injuries related to trauma, although this may be considered less feasible for use in routine practice than CTA in present practice (Wang et al., 2012). The studies included in this SLR included those published a decade ago, where DSA would have been a clear reference standard (e.g. DiCocco et al., 2011) and therefore the use of DSA in these studies was appropriate. However, other studies used expert consensus as the equivalent of a reference standard for evaluating CTA and MRA/VWI (Vranic et al., 2020), while the assessment of MRA in the study by Takano et al. (2013) was based on CTA as a reference standard with or without DSA. Hence, the lack of a consistent reference standard across studies may be considered a weakness (Ochodo et al., 2013). In particular, expert neuroradiologist consensus on outcomes is a challenging standard to apply in studies, as this is subjective in nature and reflects aspects of imaging quality and protocol use (Austein et al., 2019).

## Imaging the cervical region in trauma patients: comparison with current knowledge base

There is a need to ensure that imaging strategies are used effectively in the screening and diagnosis of cervical vascular injuries in the context of trauma given the frequency of these injuries and their implications for the patient (Bransford et al., 2014). AlBayar et al. (2019) performed a retrospective review of 729 patients with cervical spine trauma and found that penetrating trauma was linked to a 64% risk of vertebral artery injury, while blunt trauma had a 9% risk of this injury. However, the incidence may be higher in certain situations, depending on the mechanism of injury (Yoshihara et al., 2011), while in general trauma patients the incidence of clinically relevant vertebral artery injury may be as high as 30% (Merrill et al., 2020). This suggests that a substantial proportion of patients have cervical vascular injury linked to trauma. The severity of injury is a key factor determining the degree to which these vascular injuries influence care and the potential for adverse outcomes (Merrill et al., 2020). It has been noted that vascular injuries increase the risk of stroke with a mortality rate of 8–38% for carotid or vertebral artery injuries (Rutman et al., 2018).

The use of CTA is considered valuable due to the widespread availability of the technique and the non-invasive nature of the assessment process (Shiroff et al., 2013). The present review findings suggest that CTA has a relatively high sensitivity and specificity (and hence diagnostic accuracy) for the detection of cervical vascular injuries, although this is prone to some variation across studies. Variation in diagnostic accuracy appears to be reflective of the specific vascular injury assessed (e.g. carotid artery or vertebral artery injury), the imaging protocol and strategy used (including the number of slices used in the CT protocol) and the influence of interpretation and diagnostic thresholds applied to the imaging studies. Interestingly, as noted by Grandhi et al. (2017), the advances in technology over time, which may be assumed to have an impact on sensitivity of CTA for the detection of cervical vascular injuries, may not have a pronounced effect on actual diagnostic accuracy. Low sensitivity of contemporary studies, such as that by Grandhi et al. (2017) are likely related to the type of injuries and the severity of injuries assessed, which highlight the importance of considering the heterogeneous nature of cervical vascular injury, based on injury type, location and the presence of concurrent injuries, which all influence imaging sensitivity.

The findings of the present SLR are supported by the wider literature with regards to the diagnostic accuracy of CTA in cervical artery injury contexts. A meta-analysis (Roberts et al., 2013) of the use of CTA in screening for blunt cerebrovascular injury following trauma included eight studies (1426 patients) and noted that the sensitivity and specificity of CTA compared to the gold standard of

DSA was 66% and 97%, respectively. Considerable variation in the diagnostic accuracy of CTA was noted across studies, based on the number of slices used in CT scans, training level of interpreting radiologists, and different application of diagnostic thresholds for CTA positivity. Indeed, the present review noted that a higher number of slices (e.g. 64 slices versus 32 slices) was linked to an improvement in diagnostic accuracy of CTA for cervical vascular injuries (DiCocco et al., 2011; Paulus et al., 2014), supporting the findings of the meta-analysis by Roberts et al. (2013). However, evaluation of other variables, including diagnostic thresholds and radiologists training was not performed and may also contribute to the heterogeneity in CTA diagnostic accuracy noted in this review.

A meta-analysis (Karagiorgas et al., 2017) of the use of MRA in the diagnosis of blunt vertebral artery injury identified five studies, including 405 patients, all of which were prospective in design. There was substantial heterogeneity within the literature, relating to populations studied, MRA techniques used, and outcomes reported. However, the sensitivity of MRA ranged from 25–85% (mean value 55%), while the specificity ranged from 65–99% (mean value 91%). This meta-analysis largely included studies published outside of the date range of the present SLR (i.e. prior to 2011) and therefore reflects older data and imaging strategies used. However, based on the literature search completed for this SLR, there is a paucity of literature exploring MRA as a diagnostic tool in cervical vascular injury, suggesting that the potential benefits and feasibility of this imaging approach may not be actively considered in modern practice.

None of the studies included in the present review directly compared the use of MRA and CTA for the evaluation of cervical vascular injury in trauma contexts, which is a limitation of the available data set. Indeed, indirect analyses are challenging and may be complicated by the inherent difficulties in comparing conditions between studies, including patient characteristics, clinical contexts, and wider imaging technology and protocols (Geddes et al., 2016). A wider search of the literature identified only two studies where MRA and CTA were directly evaluated in the same group of patients, both of which were published in 2002, outside of the date range of the present SLR (Biffl et al., 2002; Miller et al., 2002). In the study by Biffl et al. (2002), the sensitivity of CTA was 68% versus 75% for MRA, while the specificity value was 67% for both imaging studies, when compared with the reference standard of arteriography. Miller et al. (2002) found that CTA had a sensitivity of 47% compared with 50% for MRA when focusing on carotid artery injuries and sensitivities of 53% and 47%, respectively, for vertebral artery injuries. These studies therefore suggest comparable sensitivity and specificity for CTA and MRA in the context of blunt cervical trauma, with relatively low sensitivities attributed to missed low grade injuries. However, the

studies were completed using small sample sizes, limiting power of the analyses, and reflect imaging protocols and strategies that are almost two decades old, which limits the application of these findings to current practice contexts.

Indirect comparisons of MRA and CTA are generally lacking in the contemporary literature, reflecting a paucity of recent studies utilising MRA as an imaging modality for cervical vascular injury. Rather, there is an increasing focus on utilising MR imaging, including MRA, in specific context and in conjunction with other imaging strategies, where CTA diagnostic sensitivity may be compromised or suboptimal, as considered below.

### **The use of CTA and MRA in specific cervical trauma contexts**

MRI has been considered a feasible imaging strategy for the assessment of trauma in the cervical region, particularly where there is a risk of neurological damage as well as vascular damage secondary to trauma (Karagiorgas et al., 2017). However, the diagnostic accuracy of MRA for evaluating cervical vascular injury alone needs to be considered specifically, given the established diagnostic accuracy and value of CTA in this context (Sanfilippo et al., 2018). The evidence suggests that MRA is not sufficient as a routine screening or diagnostic tool in the context of all cervical trauma (Karagiorgas et al., 2017). However, it has been suggested that MRA may be used as an alternative to CTA where available in this context and combination of CTA and MRA may be justified in some instances (Sanfilippo et al., 2018).

Although there is a lack of direct evidence supporting the use of MRA in trauma-related cervical vascular injury assessment, the wider literature suggests that aspects of imaging quality and resolution of vascular anatomy associated with MRA may be favourable compared to CTA, although this has been evaluated outside of trauma contexts. For instance, Lv et al. (2014) found that time-of-flight MRA showed a high sensitivity and specificity (79% and 95%, respectively) for detection of carotid artery stenosis, while a modified MR imaging protocol was superior to both MRA and CTA in this context. Similarly, Gupta et al. (2015) found that CTA and MRA showed comparable diagnostic accuracy for carotid artery disease detection. However, Korn et al. (2015) found that imaging quality and diagnosis of carotid pathology was more consistent with CTA than MRA in non-trauma contexts, suggesting that routine use of MRA outside of trauma contexts may not be indicated for evaluating cervical vascular injury or pathology. Additional techniques related to MRA have also emerged as potentially valuable imaging strategies compared with MRA or CTA. The use of vessel wall imaging using MR technology has also been shown to have comparable or superior diagnostic accuracy for blunt cerebrovascular injury, based on a small sample

(n=40) of patients (Vranic et al., 2020). The use of a VWI protocol has been shown to be superior for the detection of pathology associated with cervical vascular injury compared to standard MRA (Zhang et al., 2019), highlighting the value of these emerging strategies in practice. Therefore, the use of MR imaging using a vessel wall imaging protocol may represent an alternative approach to the use of this technology in trauma contexts. Further evaluation of this form of imaging, including diagnostic accuracy assessment and feasibility in practice, should be prioritised in trauma contexts (Young et al., 2019).

While it has been suggested that specific clinical features may justify the use of MRA or adjunctive MR imaging strategies (Zhang et al., 2019) there remains an important need to evaluate and clarify this tailored approach to imaging. Recent screening guidelines have highlighted the importance of judicious use of imaging techniques in trauma contexts where time-sensitive assessment is needed and complex pathology may be present (Bruns et al., 2014; Fehlings et al., 2017; Nowicki et al., 2017). Furthermore, the use of MRA and MR imaging may be useful in clarifying some pathology, but CTA is often preferred as a routine screening tool, particularly as this may guide the use of other imaging strategies accurately (Fehlings et al., 2017).

### **Practical use of MRA and CTA in trauma contexts**

The practical use both CTA and MRA in a trauma setting may inform the relative value of selecting one imaging modality over another, while taking into account diagnostic accuracy (Shetty et al., 2016). Indeed, one of the key motivating factors for exploring the use of MRA in this context was the potential benefits over CTA in terms of the imaging technique and the theoretical imaging quality that may be obtained (Clement, 2019). MRA avoids exposure to ionising radiation, which may be important in promoting patient safety, particularly if repeated scans are needed during treatment and follow-up (Even et al., 2012). Furthermore, MRA provides a high soft tissue discrimination superior to CTA in many contexts, which had the potential to facilitate more accurate diagnosis of vascular injury (Provenzale and Sarikaya, 2009). However, the diagnostic accuracy of MRA has not been demonstrated to be higher than CTA in practice and wider limitations of MRA may be considered as obstacles to use of this technology in addition to diagnostic accuracy concerns (Beckmann et al., 2019).

The key limitations associated with MRA include a long time for examination, contraindications of metalwork in a trauma context (as metallic foreign bodies preclude the use of MRA), the increased cost of the imaging protocol versus CTA, and the lack of broad availability in trauma settings (Lockwood et al., 2016). These limitations are important not only with respect to a

comparison with CTA imaging, but also in the broader context of trauma patient management (Dreger et al., 2017). Indeed, rapid tests and screening for pathology are needed in this setting, precluding the widespread use of MRA as a first-line or screening tool (Karagiorgas et al., 2017). Furthermore, where spinal trauma is suspected and neurological damage is evident, alternative strategies and rapid decision-making may be needed, precluding the use of many imaging strategies in the most urgent contexts (Beckmann et al., 2019).

### **Strengths and limitations**

One of the main strengths of this review is the structured and systematic nature of the review process, as applied to the identification and analysis of the evidence (Coughlan et al., 2013). The use of formal criteria for identifying and including studies, as well as in evaluating the quality of studies, reduces the risk of bias in the review process and increases the reliability of the method (Peters et al., 2015). Furthermore, the transparency of the method allows for reproducibility of the review process, lending further reliability to the findings (Cook and West, 2012). The inclusion criteria for the study were also advantageous in applying a clear focus to the review, with a focus on literature relating to both CTA and MRA in the assessment of cervical vascular injuries in a trauma context, while reflecting a contemporary data set. This compares with other reviews or assessments in the literature that have included older studies, or which have focused on a wider range of pathologies in a trauma context, reducing their specificity to the specific context of a patient with cervical traumatic injury (e.g. Roberts et al., 2013; Karagiorgas et al., 2017). Therefore, the strengths of this SLR reflect the systematic and contemporary nature of the enquiry, as well as clarity of the focus on a specific clinical situation.

There are some important limitations to this SLR, which should be taken into account in the formulation of recommendations for research and practice. One of the limitations is the identified of a relatively small number of studies (n=6), specifically in relation to literature on the use of MRA in the evaluation of cervical vascular injury. While this paucity of literature highlights the need for further studies in the field and reflects the specificity of the focus of the SLR, ultimately the quantity of data available limits the robustness of the conclusion that can be drawn (Caldwell, 2014).

### **Implications for research and practice**

Despite the limitations of the review and the included data set, the findings of the review do have some implications for research and practice. From a research perspective, the small number of direct studies comparing CTA and MRA in the

assessment of cervical vascular injury secondary to penetrating and/or blunt trauma suggests that there is a need for more studies of this nature to provide a valid assessment of the comparable diagnostic accuracy of CTA and MRA. There is a specific need to consider the use of MRA in general cervical trauma contexts, as well as for specific types of injury, including low grade injuries and injuries associated with fractures, where it is suggested that CTA may have more limited value (Grandhi et al., 2017). Furthermore, the use of MRA in conjunction with CTA or other MR imaging strategies, including VWI, should be evaluated for carotid and vertebral artery injury both together and individually in large groups of patients to determine how these modalities compare in practice. VWI in particular may improve diagnostic accuracy of specific lesions and utilises MRA in the imaging protocol, suggesting the need for further analysis in the evidence base (Wang et al., 2021).

From a practice perspective, the evidence is insufficient to suggest that the diagnostic accuracy of MRA is superior to CTA in the context of cervical vascular injury secondary to trauma. The diagnostic accuracy of MRA in this context is relatively low and the lack of availability of MRA across trauma contexts may continue to favour the use of CTA. This finding supports the general recommendations and guidance in the published literature, where MRA may be considered a less favourable option for cervical vascular injury than CTA or DSA (Shafafy et al., 2017; Brommeland et al., 2018; Abu Mughli et al., 2020). However, it has been suggested that the sensitivity and specificity of CTA may be inadequate for screening for some trauma contexts and that combination of CTA and MRA may overcome this limitation (Shafafy et al., 2017). However, this is unlikely to be feasible in practice and ultimately the limitations associated with practical use of MRA in trauma contexts may be a more significant barrier to use than the diagnostic accuracy of the modality.

## Conclusion

The assessment of cervical vascular injury in the context of trauma is important in preventing morbidity and mortality. The optimal imaging approach to diagnosing these injuries is an area of discussion as the widespread use of DSA has largely been supplanted by CTA. However, the relative value of MRA is unclear, although offering theoretical advantages to CTA in terms of avoiding exposure to ionising radiation. However, the diagnostic accuracy of both CTA and MRA need to be carefully evaluated to support the use of these imaging strategies in this context.

The present review identified seven studies that assessed the diagnostic accuracy of CTA or MRA in the context of cervical vascular injury in trauma

patients, following a multi-database search strategy. These studies did not directly compare the diagnostic accuracy of CTA with MRA in the context of cervical vascular injury secondary to trauma, which is a major limitation of the review and reflective of a lack of evidence in the published literature. This likely reflects the findings of older studies where MRA was considered to have inferior sensitivity and specificity for cervical vascular trauma injury diagnosis, limiting the application of this technique in practice and subsequent appearance of data in clinical studies. Therefore, the lack of contemporary data on the use of MRA reflects a shift in focus towards the use of CTA in practice, justified based on early research findings and improving diagnostic accuracy as technology advances. However, MRA remained in use in specific contexts and in combination with other MR imaging approaches, allowing for some analysis of relative diagnostic value of these approaches in the present review.

The diagnostic accuracy of CTA for cervical vascular injury in trauma patients was assessed in five of the included studies, typically in the context of blunt traumatic injuries, with one study (Ares et al., 2019) focusing on penetrating injuries. Overall, the findings suggested that the diagnostic accuracy of CTA was high compared to DSA, with a moderate to high sensitivity and high specificity for lesion diagnosis. Advances in imaging technology and in user experience with CTA in this clinical context appears to be associated with increased diagnostic accuracy and has led to CTA emerging as a key screening and diagnostic tool in practice, often in the place of the more invasive DSA procedure.

The diagnostic accuracy of MRA was not assessed in detail in the included literature and none of the studies provided a clear and robust assessment of MRA with CTA in this context. While MRA findings may be linked to increased diagnostic accuracy in specific contexts, including intramural haematoma detection and demonstrates a high level of agreement with expert consensus in equivocal CTA findings, overall the wider literature suggests that MRA may lack suitable sensitivity and specific for routine use in assessment of cervical trauma.

Furthermore, the practical and clinical implications of using CTA or MRA for cervical vascular injury assessment in trauma patients need to be considered in justifying the use of specific approaches in practice. While MRA has advantages of not requiring contrast medium, potentially increased soft tissue imaging quality, and avoiding exposure to ionising radiation, the time needed for examinations, the limited availability compared to CTA, and the contraindications in trauma contexts (e.g. metallic foreign bodies in penetrating trauma) may limit the use of MRA in practical settings. However, where neurological damage is suspected and other indications support the use of MRA, this may be a valuable tool in practice and preferable to CTA.

The research and practice implications of this SLR are discussed in detail and include the need for more studies evaluating the use of MRA specifically in trauma contexts, including the use of MRA with adjunctive MR imaging strategies, such as VWI. Research comparing the use of CTA and MRA directly in trauma contexts may be challenging to justify given widespread adoption of CTA as a screening tool of choice, with little evidence supporting the use of MRA in this context. Unless MRA becomes more widespread in nature and used routinely in trauma contexts, CTA is likely to be the preferred imaging modality for the majority of patients. Practitioners in trauma contexts need to consider not only the potential for cervical vascular injury but also additional injuries and wider aspects of trauma-related injuries that may be of relevance for management. The use of CTA may be preferred depending on the wider context of injuries and the need for rapid patient assessment in trauma contexts. However, MRA may equally be valued where specific indications for MRA are relevant to wider trauma outcomes. Furthermore, practitioners need to balance not only the diagnostic accuracy of these studies for the detection of lesions in cervical vasculature, but also the relevance of these diagnoses for patient care and outcomes in the wider trauma context. Hence, there will always be limitations to assessing imaging protocols in the context of traumatic injury when focusing one specific aspect of trauma or injury site.

Given the complexity of trauma assessment and the risks associated with cervical vasculature injury, including a risk of stroke, practice and policy need to be aligned to support decision-making in emergency contexts. There is an important need for refinement of imaging protocols and trauma imaging guidelines to take into account the relative advantages and disadvantages of these imaging modalities in specific trauma contexts to optimise patient diagnosis and subsequent management.

## References

- Aagaard, T., Lund, H., & Juhl, C. (2016). Optimizing literature search in systematic reviews— are MEDLINE, EMBASE and CENTRAL enough for identifying effect studies within the area of musculoskeletal disorders?. *BMC Medical Research Methodology*, 16(1), 1-11.
- Abu Mughli, R., Wu, T., Li, J., Moghimi, S., Alem, Z., Nasir, M. U., & Nicolaou, S. (2020). An Update in Imaging of Blunt Vascular Neck Injury. *Canadian Association of Radiologists Journal*, 71(3), 281-292.
- AlBayar, A., Sullivan, P. Z., Blue, R., Leonard, J., Kung, D. K., Ozturk, A. K., & Schuster, J. M. (2019). Risk of vertebral artery injury and stroke following blunt and penetrating cervical spine trauma: a retrospective review of 729 patients. *World Neurosurgery*, 130, e672-e679.
- Ares, W. J., Jankowitz, B. T., Tonetti, D. A., Gross, B. A., & Grandhi, R. (2019). A comparison of digital subtraction angiography and computed tomography angiography for the diagnosis of penetrating cerebrovascular injury. *Neurosurgical Focus*, 47(5), E16.
- Aromataris, E., & Riitano, D. (2014). Constructing a search strategy and searching for evidence. *American Journal of Nursing*, 114(5), 49-56.
- Austein, F., Wodarg, F., Jürgensen, N., Huhndorf, M., Meyne, J., Lindner, T., & Riedel, C. (2019). Automated versus manual imaging assessment of early ischemic changes in acute stroke: comparison of two software packages and expert consensus. *European Radiology*, 29(11), 6285-6292.
- Aveyard, H. (2014). *Doing a literature review in health and social care: A practical guide*. London: MacMillan
- Bankhead, C. R., & Stevens, R. J. (2018). Critical appraisal of database studies. *Critical Appraisal for Primary Care*, 12, 1-10
- Beckmann, N. M., West, O. C., Nunez Jr, D., Kirsch, C. F., Aulino, J. M., Broder, J. S., & Bykowski, J. (2019). ACR appropriateness criteria® suspected spine trauma. *Journal of the American College of Radiology*, 16(5), S264-S285.
- Bettany-Saltikov, J. (2012). *How to do a Systematic Literature Review in Nursing: A step-by-step guide*. London: Springer
- Biffi, W. L., Moore, E. E., Offner, P. J., Brega, K. E., Franciose, R. J., & Burch, J. M. (1999). Blunt carotid arterial injuries: implications of a new grading scale. *Journal of Trauma and Acute Care Surgery*, 47(5), 845-855
- Biffi, W. L., Ray Jr, C. E., Moore, E. E., Mestek, M., Johnson, J. L., & Burch, J. M. (2002). Noninvasive diagnosis of blunt cerebrovascular injuries: a preliminary report. *Journal of Trauma and Acute Care Surgery*, 53(5), 850-856.
- Blankenbaker, D. G. (2016). *Diagnostic Imaging: Musculoskeletal Non-Traumatic Disease E-Book*. London: Elsevier Health Sciences.
- Boswell, C., & Cannon, S. (2018). *Introduction to nursing research*. New York: Jones & Bartlett Learning.
- Bowling, A. (2014). *Research methods in health: investigating health and health services*. London: McGraw-hill education (UK).

- Bramer, W. M., Rethlefsen, M. L., Kleijnen, J., & Franco, O. H. (2017). Optimal database combinations for literature searches in systematic reviews: a prospective exploratory study. *Systematic Reviews*, 6(1), 1-12.
- Bransford, R. J., Alton, T. B., Patel, A. R., & Bellabarba, C. (2014). Upper cervical spine trauma. *JAAOS-Journal of the American Academy of Orthopaedic Surgeons*, 22(11), 718-729.
- Brommeland, T., Helseth, E., Aarhus, M., Moen, K. G., Dyrskog, S., Bergholt, B., & Jeppesen, E. (2018). Best practice guidelines for blunt cerebrovascular injury (BCVI). *Scandinavian Journal of Trauma, Resuscitation and Emergency Medicine*, 26(1), 1-10.
- Bruns, B. R., Tesoriero, R., Kufera, J., Sliker, C., Laser, A., Scalea, T. M., & Stein, D. M. (2014). Blunt cerebrovascular injury screening guidelines: what are we willing to miss?. *Journal of Trauma and Acute Care Surgery*, 76(3), 691-695
- Bryman, A. (2016). *Social research methods*. Oxford: Oxford university press.
- Buerke, B., Tombach, B., Stoll, W., Heindel, W., & Niederstadt, T. (2007). Magnetic resonance angiography follow-up examinations to detect iatrogenic pseudoaneurysms following otorhinolaryngological surgery. *The Journal of Laryngology and Otology*, 121(7), 698.
- Caldwell, D. M. (2014). An overview of conducting systematic reviews with network meta-analysis. *Systematic Reviews*, 3(1), 1-4.
- Campbell, M., McKenzie, J. E., Sowden, A., Katikireddi, S. V., Brennan, S. E., Ellis, S., & Thomson, H. (2020). Synthesis without meta-analysis (SWiM) in systematic reviews: reporting guideline. *BMJ*, 368, 1-10
- Clement, M. O. (2019). Imaging of brain trauma. *Radiologic Clinics*, 57(4), 733-744.
- Cohen, J. F., Korevaar, D. A., Gatsonis, C. A., Glasziou, P. P., Hooft, L., Moher, D., & Bossuyt, P. M. (2017). STARD for Abstracts: essential items for reporting diagnostic accuracy studies in journal or conference abstracts. *BMJ*, 358, 1-10
- Cook, D. A., & West, C. P. (2012). Conducting systematic reviews in medical education: a stepwise approach. *Medical Education*, 46(10), 943-952.
- Coughlan, M., Cronin, P., & Ryan, F. (2013). *Doing a Literature Review in Nursing, Health and Social Care*. London: SAGE Publications.
- Creswell, J. W., & Creswell, J. D. (2017). *Research design: Qualitative, quantitative, and mixed methods approaches*. London: Sage publications
- Cronin, P., Kelly, A. M., Altaee, D., Foerster, B., Petrou, M., & Dwamena, B. A. (2018). How to perform a systematic review and meta-analysis of diagnostic imaging studies. *Academic Radiology*, 25(5), 573-593.
- Dawson, C. (2019). *Introduction to Research Methods 5th Edition: A Practical Guide for Anyone Undertaking a Research Project*. New York: Robinson
- Dreger, T., Place, H., Mattingly, T., Piper, C., & Brechbuehler, J. (2017). Analysis of cervical angiograms in cervical spine trauma patients, does it make a difference?. *Clinical Spine Surgery*, 30(5), 232-235.

- Dunn, C. J., Changoor, S., Issa, K., Moore, J., Moontasri, N. J., Faloon, M. J., & Emami, A. (2020). Cervical Computed Tomography Angiography Rarely Leads to Intervention in Patients With Cervical Spine Fractures. *Global Spine Journal*, 21, 1-10
- Eastman, A. L., Chason, D. P., Perez, C. L., McAnulty, A. L., & Minei, J. P. (2006). Computed tomographic angiography for the diagnosis of blunt cervical vascular injury: is it ready for primetime?. *Journal of Trauma and Acute Care Surgery*, 60(5), 925-929.
- Elamin, M. B., & Montori, V. M. (2012). The hierarchy of evidence: from unsystematic clinical observations to systematic reviews. *Neurology*, 33, 11-24
- Eusebi, P. (2013). Diagnostic accuracy measures. *Cerebrovascular Diseases*, 36(4), 267-272.
- Evans, C., Chaplin, T., & Zelt, D. (2018). Management of major vascular injuries: neck, extremities, and other things that bleed. *Emergency Medicine Clinics*, 36(1), 181-202.
- Even, J., McCullough, K., Braly, B., Hohl, J., Song, Y., Lee, J., & Devin, C. (2012). Clinical indications for arterial imaging in cervical trauma. *Spine*, 37(4), 286-291.
- Fakhry, S. M., Jaques, P. F., & Proctor, H. J. (1988). Cervical vessel injury after blunt trauma. *Journal of Vascular Surgery*, 8(4), 501-508.
- Fehlings, M. G., Martin, A. R., Tetreault, L. A., Aarabi, B., Anderson, P., Arnold, P. M., and Harrop, J. S. (2017). A clinical practice guideline for the management of patients with acute spinal cord injury: recommendations on the role of baseline magnetic resonance imaging in clinical decision making and outcome prediction. *Global Spine Journal*, 7(3\_suppl), 221S-230S.
- Feliciano, D. V. (2015). Penetrating cervical trauma. *World Journal of Surgery*, 39(6), 1363-1372.
- Feliciano, D. V. (2017). For the patient—Evolution in the management of vascular trauma. *Journal of Trauma and Acute Care Surgery*, 83(6), 1205-1212.
- Figueiredo, G., Brockmann, C., Boll, H., Heilmann, M., Schambach, S. J., Fiebig, T., & Brockmann, M. A. (2012). Comparison of digital subtraction angiography, micro-computed tomography angiography and magnetic resonance angiography in the assessment of the cerebrovascular system in live mice. *Clinical Neuroradiology*, 22(1), 21-28.
- Fourman, M. S., Shaw, J. D., Vaudreuil, N. J., Dombrowski, M. E., Wawrose, R. A., Boakye, L. A., & Donaldson III, W. F. (2019). Cervical Spine Fractures: Who Really Needs CT Angiography?. *Spine*, 44(23), 1661-1667.
- Garrard, J. (2020). Health sciences literature review made easy. London: Elsevier
- Geddes, A. E., Burlew, C. C., Wagenaar, A. E., Biff, W. L., Johnson, J. L., Pieracci, F. M., & Moore, E. E. (2016). Expanded screening criteria for blunt cerebrovascular injury: a bigger impact than anticipated. *The American Journal of Surgery*, 212(6), 1167-1174.
- Goldzweig, C. L., Orshansky, G., Paige, N. M., Miake-Lye, I. M., Beroes, J. M., Ewing, B. A., & Shekelle, P. G. (2015). Electronic health record-based interventions for improving appropriate diagnostic imaging: a systematic review and meta-analysis. *Annals of Internal Medicine*, 162(8), 557-565.

- Gracias, V. H., Reilly, P. M., Philpott, J., Klein, W. P., Lee, S. Y., Singer, M., & Schwab, C. W. (2001). Computed tomography in the evaluation of penetrating neck trauma: a preliminary study. *Archives of Surgery, 136*(11), 1231-1235.
- Grandhi, R., Weiner, G. M., Agarwal, N., Panczykowski, D. M., Ares, W. J., Rodriguez, J. S., & Jankowitz, B. T. (2017). Limitations of multidetector computed tomography angiography for the diagnosis of blunt cerebrovascular injury. *Journal of Neurosurgery, 128*(6), 1642-1647.
- Greenspan, A., & Beltran, J. (2020). *Orthopaedic Imaging: A practical approach*. New York: Lippincott Williams & Wilkins.
- Grove, S. K., & Gray, J. R. (2018). *Understanding Nursing Research E-Book: Building an Evidence-Based Practice*. London: Elsevier Health Sciences.
- Gupta, A., Baradaran, H., Mtui, E. E., Kamel, H., Pandya, A., Giambone, A., & Sanelli, P. C. (2015). Detection of symptomatic carotid plaque using source data from MR and CT angiography: a correlative study. *Cerebrovascular Diseases, 39*(3-4), 151-161.
- Hagedorn, J. C., Emery, S. E., France, J. C., & Daffner, S. D. (2014). Does CT angiography matter for patients with cervical spine injuries?. *JBJS, 96*(11), 951-955.
- Hagspiel, K. D., Flors, L., Hanley, M., & Norton, P. T. (2015). Computed tomography angiography and magnetic resonance angiography imaging of the mesenteric vasculature. *Techniques in Vascular and Interventional Radiology, 18*(1), 2-13.
- Han, K., Song, K., & Choi, B. W. (2016). How to develop, validate, and compare clinical prediction models involving radiological parameters: study design and statistical methods. *Korean Journal of Radiology, 17*(3), 339-349
- Hanning, U., Sporns, P. B., Schmiedel, M., Ringelstein, E. B., Heindel, W., Wiendl, H., & Dittrich, R. (2017). CT versus MR techniques in the detection of cervical artery dissection. *Journal of Neuroimaging, 27*(6), 607-612.
- Hart, C. (2018). *Doing a literature review: Releasing the research imagination*. London: Sage
- Hollingworth, W., Nathens, A. B., Kanne, J. P., Crandall, M. L., Crummy, T. A., Hallam, D. K., & Jarvik, J. G. (2003). The diagnostic accuracy of computed tomography angiography for traumatic or atherosclerotic lesions of the carotid and vertebral arteries: a systematic review. *European Journal of Radiology, 48*(1), 88-102.
- Hussain, M., & Javed, G. (2011). Diagnostic accuracy of clinical examination in cervical spine injuries in awake and alert blunt trauma patients. *Asian Spine Journal, 5*(1), 10.
- Ingham-Broomfield, R. (2016). A nurses' guide to the hierarchy of research designs and evidence. *Australian Journal of Advanced Nursing, 33*(3), 38-48
- Jacob, R., Cox, M., Koral, K., Greenwell, C., Xi, Y., Vinson, L., & Booth, T. N. (2016). MR imaging of the cervical spine in nonaccidental trauma: a tertiary institution experience. *American Journal of Neuroradiology, 37*(10), 1944-1950.
- Jenkins, L. N., & Rezende-Neto, J. B. (2020). Current Management of Penetrating Traumatic Cervical Vascular Injuries. *Current Surgery Reports, 8*, 1-8.
- Jesson, J., Matheson, L., & Lacey, F. M. (2011). *Doing your literature review: Traditional and systematic techniques*. London: Springer

- Kable, A. K., Pich, J., & Maslin-Prothero, S. E. (2012). A structured approach to documenting a search strategy for publication: A 12 step guideline for authors. *Nurse Education Today*, 32(8), 878-886.
- Karagiorgas, G. P., Brotis, A. G., Giannis, T., Rountas, C. D., Vassiou, K. G., Fountas, K. N., & Kapsalaki, E. Z. (2017). The diagnostic accuracy of magnetic resonance angiography for blunt vertebral artery injury detection in trauma patients: a systematic review and meta-analysis. *Clinical Neurology and Neurosurgery*, 160, 152-163.
- Karkada, S. (2015). Evidence based practice (EBP). *International Journal of Nursing Research and Practice*, 2(2), 2-4.
- Kasbekar, A. V., Combellack, E. J., Derbyshire, S. G., & Swift, A. C. (2017). Penetrating neck trauma and the need for surgical exploration: six-year experience within a regional trauma centre. *The Journal of Laryngology & Otology*, 131(1), 8-12.
- Kim, J. H., van Rijn, R. M., van Tulder, M. W., Koes, B. W., de Boer, M. R., Ginai, A. Z., & Verhagen, A. P. (2018). Diagnostic accuracy of diagnostic imaging for lumbar disc herniation in adults with low back pain or sciatica is unknown; a systematic review. *Chiropractic & Manual Therapies*, 26(1), 1-14.
- Korn, A., Bender, B., Brodoefel, H., Hauser, T. K., Danz, S., Ernemann, U., & Thomas, C. (2015). Grading of carotid artery stenosis in the presence of extensive calcifications: dual-energy CT angiography in comparison with contrast-enhanced MR angiography. *Clinical Neuroradiology*, 25(1), 33-40.
- LeBlang, S. D., & Nunez Jr, D. B. (2000). Noninvasive imaging of cervical vascular injuries. *American Journal of Roentgenology*, 174(5), 1269-1278.
- Lisy, K., & Porritt, K. (2016). Narrative synthesis: considerations and challenges. *International Journal of Evidence-Based Healthcare*, 14(4), 1-10
- LoBiondo-Wood, G., & Haber, J. (2017). Nursing research-e-book: methods and critical appraisal for evidence-based practice. London: Elsevier Health Sciences.
- Lockwood, M. M., Smith, G. A., Tanenbaum, J., Lubelski, D., Seicean, A., Pace, J., & Steinmetz, M. P. (2016). Screening via CT angiogram after traumatic cervical spine fractures: narrowing imaging to improve cost effectiveness. Experience of a Level I trauma center. *Journal of Neurosurgery: Spine*, 24(3), 490-495.
- Long, B., April, M. D., Summers, S., & Koyfman, A. (2017). Whole body CT versus selective radiological imaging strategy in trauma: an evidence-based clinical review. *The American Journal of Emergency Medicine*, 35(9), 1356-1362.
- Lv, P., Lin, J., Guo, D., Liu, H., Tang, X., Fu, C., & Hu, J. (2014). Detection of carotid artery stenosis: a comparison between 2 unenhanced MRAs and dual-source CTA. *American Journal of Neuroradiology*, 35(12), 2360-2365.
- Mair, G., von Kummer, R., Adami, A., White, P. M., Adams, M. E., Yan, B., & Wardlaw, J. M. (2017). Arterial obstruction on computed tomographic or magnetic resonance angiography and response to intravenous thrombolytics in ischemic stroke. *Stroke*, 48(2), 353-360.
- Mallett, S., Halligan, S., Thompson, M., Collins, G. S., & Altman, D. G. (2012). Interpreting diagnostic accuracy studies for patient care. *BMJ*, 345, 1-10

- Meghoo, C. A., Dennis, J. W., Tuman, C., & Fang, R. (2012). Diagnosis and management of evacuated casualties with cervical vascular injuries resulting from combat-related explosive blasts. *Journal of Vascular Surgery*, 55(5), 1329-1337.
- Merrill, S., Clifton, W., Valero-Moreno, F., Damon, A., & Rahmathulla, G. (2020). Vertebral artery injury with coinciding unstable cervical spine trauma: mechanisms, evidence-based management, and treatment options. *Cureus*, 12(3), 1-10
- Mills, A. M., Raja, A. S., & Marin, J. R. (2015). Optimizing diagnostic imaging in the emergency department. *Academic Emergency Medicine*, 22(5), 625-631.
- Mohammed, G. S., Pillay, W. R., Barker, P., & Robbs, J. V. (2004). The role of clinical examination in excluding vascular injury in haemodynamically stable patients with gunshot wounds to the neck. A prospective study of 59 patients. *European Journal of Vascular and Endovascular surgery*, 28(4), 425-430.
- Moher, D., Shamseer, L., Clarke, M., Ghersi, D., Liberati, A., Petticrew, M., & Stewart, L. A. (2015). Preferred reporting items for systematic review and meta-analysis protocols (PRISMA-P) 2015 statement. *Systematic Reviews*, 4(1), 1-9.
- Morales-Uribe, C., Ramírez, A., Suarez-Poveda, T., Ortiz, M., & Sanabria, A. (2016). Diagnostic performance of CT angiography in neck vessel trauma: systematic review and meta-analysis. *Emergency Radiology*, 23(5), 421-431.
- Moule, P., Aveyard, H., & Goodman, M. (2016). *Nursing research: An introduction*. London: Sage.
- Munera, F., Soto, J. A., Palacio, D. M., Castañeda, J., Morales, C., Sanabria, A., & García, G. (2002). Penetrating neck injuries: helical CT angiography for initial evaluation. *Radiology*, 224(2), 366-372.
- Munera, F., Soto, J. A., Palacio, D., Velez, S. M., & Medina, E. (2000). Diagnosis of arterial injuries caused by penetrating trauma to the neck: comparison of helical CT angiography and conventional angiography. *Radiology*, 216(2), 356-362.
- Munn, Z., Tufanaru, C., & Aromataris, E. (2014). JBI's systematic reviews: data extraction and synthesis. *AJN The American Journal of Nursing*, 114(7), 49-54.
- Nowicki, J. L., Stew, B., & Ooi, E. (2017). Penetrating neck injuries: a guide to evaluation and management. *The Annals of The Royal College of Surgeons of England*, 100(1), 6-11.
- O'Brien, P. J., & Cox, M. W. (2011). A modern approach to cervical vascular trauma. *Perspectives in Vascular Surgery and Endovascular Therapy*, 23(2), 90-97.
- Ochodo, E. A., de Haan, M. C., Reitsma, J. B., Hooft, L., Bossuyt, P. M., & Leeftang, M. M. (2013). Overinterpretation and misreporting of diagnostic accuracy studies: evidence of "spin". *Radiology*, 267(2), 581-588.
- Ofer, A., Nitecki, S. S., Braun, J., Daitzchman, M., Goldsher, D., Hoffman, A., & Engel, A. (2001). CT angiography of the carotid arteries in trauma to the neck. *European Journal of Vascular and Endovascular Surgery*, 21(5), 401-407.
- Patel, R. R., Adam, R., Maldjian, C., Lincoln, C. M., Yuen, A., & Arneja, A. (2012). Cervical carotid artery dissection: current review of diagnosis and treatment. *Cardiology in Review*, 20(3), 145-152.

- Patterson, B. O., Holt, P. J., Cleanthis, M., Tai, N., Carrell, T., & Loosemore, T. M. (2012). Imaging vascular trauma. *Journal of British Surgery*, 99(4), 494-505.
- Payabvash, S., McKinney, A. M., McKinney, Z. J., Palmer, C. S., & Truwit, C. L. (2014). Screening and detection of blunt vertebral artery injury in patients with upper cervical fractures: the role of cervical CT and CT angiography. *European Journal of Radiology*, 83(3), 571-577.
- Peters, M. D. (2015). Not just a phase: JBI systematic review protocols. *JBI Evidence Synthesis*, 13(2), 1-2.
- Peters, M. D., Godfrey, C. M., Khalil, H., McInerney, P., Parker, D., & Soares, C. B. (2015). Guidance for conducting systematic scoping reviews. *JBI Evidence Implementation*, 13(3), 141-146.
- Phan, K., Tian, D. H., Cao, C., Black, D., & Yan, T. D. (2015). Systematic review and meta-analysis: techniques and a guide for the academic surgeon. *Annals of Cardiothoracic Surgery*, 4(2), 112-119
- Popay, J., Roberts, H., Sowden, A., Petticrew, M., Arai, L., Rodgers, M., & Duffy, S. (2006). Guidance on the conduct of narrative synthesis in systematic reviews. *ESRC Methods Programme*, 1, b92.
- Porrirt, K., Gomersall, J., & Lockwood, C. (2014). JBI's systematic reviews: study selection and critical appraisal. *AJN The American Journal of Nursing*, 114(6), 47-52.
- Provenzale, J. M., & Sarikaya, B. (2009). Comparison of test performance characteristics of MRI, MR angiography, and CT angiography in the diagnosis of carotid and vertebral artery dissection: a review of the medical literature. *American Journal of Roentgenology*, 193(4), 1167-1174.
- Remler, D. K., & Van Ryzin, G. G. (2014). *Research methods in practice: Strategies for description and causation*. London: Sage Publications.
- Roon, A. J., & Christensen, N. (1979). Evaluation and treatment of penetrating cervical injuries. *The Journal of Trauma*, 19(6), 391-397.
- Rutman, A. M., Vranic, J. E., & Mossa-Basha, M. (2018). Imaging and management of blunt cerebrovascular injury. *Radiographics*, 38(2), 542-563.
- Saito, N., Hito, R., Burke, P. A., & Sakai, O. (2014). Imaging of penetrating injuries of the head and neck: current practice at a level I trauma center in the United States. *The Keio Journal of Medicine*, 63(2), 23-33.
- Schneider, Z., Whitehead, D., LoBiondo-Wood, G., Faan, P. R., Haber, J., & Faan, P. R. (2016). *Nursing and midwifery research: Methods and appraisal for evidence based practice*. London: Elsevier.
- Schroeder, J. W., Baskaran, V., & Aygun, N. (2010). Imaging of traumatic arterial injuries in the neck with an emphasis on CTA. *Emergency Radiology*, 17(2), 109-122.
- Sclafani, S. J., Cavaliere, G., Atweh, N., Duncan, A. O., & Scalea, T. (1991). The Role of Angiography in Penetrating Neck Trauma. *The Journal of Trauma*, 31(4), 557-563.
- Seth, R., Obuchowski, A. M., & Zoarski, G. H. (2013). Endovascular repair of traumatic cervical internal carotid artery injuries: a safe and effective treatment option. *American Journal of Neuroradiology*, 34(6), 1219-1226.

- Shafafy, R., Suresh, S., Afolayan, J. O., Vaccaro, A. R., & Panchmatia, J. R. (2017). Blunt vertebral vascular injury in trauma patients: ATLS® recommendations and review of current evidence. *Journal of Spine Surgery*, 3(2), 217.
- Shahan, C. P., Magnotti, L. J., Stickley, S. M., Weinberg, J. A., Hendrick, L. E., Uhlmann, R. A., & Fabian, T. C. (2016). A safe and effective management strategy for blunt cerebrovascular injury: avoiding unnecessary anticoagulation and eliminating stroke. *Journal of Trauma and Acute Care Surgery*, 80(6), 915-922.
- Shetty, V. S., Reis, M. N., Aulino, J. M., Berger, K. L., Broder, J., Choudhri, A. F., & Bykowski, J. (2016). ACR appropriateness criteria head trauma. *Journal of the American College of Radiology*, 13(6), 668-679.
- Shiroff, A. M., Gale, S. C., Martin, N. D., Marchalik, D., Petrov, D., Ahmed, H. M., & Gracias, V. H. (2013). Penetrating neck trauma: a review of management strategies and discussion of the 'No Zone' approach. *The American Surgeon*, 79(1), 23-29.
- Siau, R. T., Moore, A., Ahmed, T., Lee, M. S., & Tostevin, P. (2013). Management of penetrating neck injuries at a London trauma centre. *European Archives of Oto-rhinolaryngology*, 270(7), 2123-2128.
- Simon, T., & Brown, K. (2020). Endovascular Management of Cervical Vascular Trauma. In *Endovascular Resuscitation and Trauma Management* (pp. 35-48). London: Springer
- Sporns, P. B., Niederstadt, T., Heindel, W., Raschke, M. J., Hartensuer, R., Dittrich, R., & Hanning, U. (2019). Imaging of spontaneous and traumatic cervical artery dissection. *Clinical Neuroradiology*, 29(2), 269-275.
- Stovold, E., Beecher, D., Foxlee, R., & Noel-Storr, A. (2014). Study flow diagrams in Cochrane systematic review updates: an adapted PRISMA flow diagram. *Systematic Reviews*, 3(1), 1-5.
- Strickland, M., Roedel, E., & Inaba, K. (2019). Penetrating cervical vascular injuries. *Current Trauma Reports*, 5(1), 40-47.
- Tan, M. A., DeVeber, G., Kirton, A., Vidarsson, L., MacGregor, D., & Shroff, M. (2009). Low detection rate of craniocervical arterial dissection in children using time-of-flight magnetic resonance angiography: causes and strategies to improve diagnosis. *Journal of Child Neurology*, 24(10), 1250-1257.
- Taneichi, H., Suda, K., Kajino, T., & Kaneda, K. (2005). Traumatically induced vertebral artery occlusion associated with cervical spine injuries: prospective study using magnetic resonance angiography. *Spine*, 30(17), 1955-1962.
- Tanon, A. A., Champagne, F., Contandriopoulos, A. P., Pomey, M. P., Vadeboncoeur, A., & Nguyen, H. (2010). Patient safety and systematic reviews: finding papers indexed in MEDLINE, EMBASE and CINAHL. *BMJ Quality & Safety*, 19(5), 452-461.
- Thomas, A. N., Goodman, P. C., & Roon, A. J. (1978). Role of angiography in cervicothoracic trauma. *The Journal of Thoracic and Cardiovascular Surgery*, 76(5), 633-638.
- Tobert, D. G., Le, H. V., Blucher, J. A., Harris, M. B., & Schoenfeld, A. J. (2018). The clinical implications of adding CT angiography in the evaluation of cervical spine fractures: a propensity-matched analysis. *JBJS*, 100(17), 1490-1495.

- Vaccaro, A. R., Klein, G. R., Flanders, A. E., Albert, T. J., Balderston, R. A., & Cotler, J. M. (1998). Long-term evaluation of vertebral artery injuries following cervical spine trauma using magnetic resonance angiography. *Spine*, 23(7), 789-794.
- Van Waes, O. J., Cheriex, K. C. A. L., Navsaria, P. H., Van Riet, P. A., Nicol, A. J., & Vermeulen, J. (2012). Management of penetrating neck injuries. *Journal of British Surgery*, 99(Supplement\_1), 149-154.
- Varga-Szemes, A., Wichmann, J. L., Schoepf, U. J., Suranyi, P., De Cecco, C. N., Muscogiuri, G., & Todoran, T. M. (2017). Accuracy of noncontrast quiescent-interval single-shot lower extremity MR angiography versus CT angiography for diagnosis of peripheral artery disease: comparison with digital subtraction angiography. *JACC: Cardiovascular Imaging*, 10(10 Part A), 1116-1124.
- Vranic, J. E., Huynh, T. J., Fata, P., Barber, J., Bonow, R. H., Levitt, M. R., & Mossa-Basha, M. (2020). The ability of magnetic resonance black blood vessel wall imaging to evaluate blunt cerebrovascular injury following acute trauma. *Journal of Neuroradiology*, 47(3), 210-215.
- Wakao, N., Takeuchi, M., Nishimura, M., Riew, K. D., Kamiya, M., Hirasawa, A., & Takayasu, M. (2014). Vertebral artery variations and osseous anomaly at the C1-2 level diagnosed by 3D CT angiography in normal subjects. *Neuroradiology*, 56(10), 843-849.
- Wang, G., Li, C., Piao, J., Xu, B., & Yu, J. (2021). Endovascular treatment of blunt injury of the extracranial internal carotid artery: the prospect and dilemma. *International Journal of Medical Sciences*, 18(4), 944-955
- Weller, S. J., Rossitch, E., & Malek, A. M. (1999). Detection of vertebral artery injury after cervical spine trauma using magnetic resonance angiography. *Journal of Trauma and Acute Care Surgery*, 46(4), 660-666.
- Whiting, P. F., Rutjes, A. W., Westwood, M. E., Mallett, S., Deeks, J. J., Reitsma, J. B., & Bossuyt, P. M. (2011). QUADAS-2: a revised tool for the quality assessment of diagnostic accuracy studies. *Annals of Internal Medicine*, 155(8), 529-536.
- Yang, Y. M., Feng, X., Yao, Z. W., Tang, W. J., Liu, H. Q., & Zhang, L. (2008). Magnetic resonance angiography of carotid and cerebral arterial occlusion in rats using a clinical scanner. *Journal of Neuroscience Methods*, 167(2), 176-183.
- Yoshihara, H., Van der Heiden, T. F., Harasaki, Y., Beauchamp, K. M., & Stahel, P. F. (2011). Fatal outcome after brain stem infarction related to bilateral vertebral artery occlusion-case report of a detrimental complication of cervical spine trauma. *Patient Safety in Surgery*, 5(1), 1-5.
- Young, C. C., Bonow, R. H., Barros, G., Mossa-Basha, M., Kim, L. J., & Levitt, M. R. (2019). Magnetic resonance vessel wall imaging in cerebrovascular diseases. *Neurosurgical Focus*, 47(6), E4-10